

MORPHOLOGICAL CHANGES OF TESTES IN ZINC DEFICIENT BOARS

CIGÁNKOVÁ VIERA, MESÁROŠ P, ALMÁŠIOVÁ VIERA and BÍREŠ J

Department of Anatomy, Histology and Physiology, University of Veterinary Medicine, Kosice, Slovak Republic

(Received 27. May 2007)

The aim of our study was to describe the morphological changes in the boar testes affected with hypozincaemia that was induced by zinc-deficient feed (barley meal). Our experiment was carried out on eight (n=8) 8-month old boars of Slovak large white breed. For 100 days the animals were fed only barley meal and had free access to drinking water. Before inclusion in the experiment, all animals were examined for serum zinc level by the method of atomic absorption spectrophotometry. Zinc serum levels in boars determined before the experiment reached $20.10 \pm 1.72 \mu\text{M}$. After 100 days of feeding barley meal the zinc level was $8.97 \pm 1.65 \mu\text{M}$ which indicated hypozincaemia. By day 20 after parenteral application of Zindep inj. (Biotika, SR), the level of zinc increased to $22.13 \pm 1.45 \mu\text{M}$ and by 60d it showed again a slight decrease to $18.46 \pm 1.056 \mu\text{M}$. The concentration of zinc in the barley meal was 30.14 mg/kg. Deficiency of zinc caused degeneration and depletion of the seminiferous epithelium and morphological changes in Sertoli cells. Seminiferous tubules were damaged to a variable degree. Morphological changes were observed also in Leydig cells and the number of malformed spermatids was increased. Zinc deficiency was accompanied with anorexia, growth disorders, and parakeratosis. A single parenteral application of the preparation Zindep[®] inj. at a dose of 0.2 mgZn/kg body weight resulted in a partial restoration of spermatogenesis within 20 days and complete recovery within 60 days following treatment.

Key words: boar, zinc deficit, testes, light and electron microscopy

INTRODUCTION

Zinc is a very important microelement for growth, reproduction, skin integrity, as immunomodulator in the protection against infections, wounds healing and tissue regeneration. Zinc deficit may develop as a consequence of its insufficient supply with feed, or its decreased absorption. Zinc is a part of many metalloenzymes and its binding to the proteinaceous part of enzymes results in its structural, catalytical, and regulatory roles (Bíreš and Vrzgula, 1988). Zinc deficiency in young males causes atrophy of testes which is manifested primarily by hypogonadism (Mc Clain *et al.*, 1984). Insufficient zinc levels in sexually mature males induces spermatogenesis disorders, as reported for humans (Silvestroni *et al.*, 1989), mice (Ueda *et al.*, 1991), rams, bulls (Mesároš *et al.*, 1994; 1999) and

stallions (Cigánková *et al.*, 1998). Well-known is the biochemical relationship between zinc and vitamin A which is mediated by alcohol dehydrogenase and affects significantly not only the process of spermatogenesis but also keratinization of skin and tissues.

The body of information about diseases causing subfertility or infertility in boars is considerably smaller than that concerning the same problem in other species of farm animals. There are several factors which are responsible for such a situation. The most important are the limited possibility of clinical examination of the sexual apparatus of adult boars and the castration performed in the majority of boars at an early age.

This study is focused on the morphology of boars testes in which hypozincaemia had been identified by biochemical analyses. We evaluated the influence of a single administration of Zindep[®] inj. i.e. a preparation based on elemental zinc and zinc oxide, with regard to the blood level of zinc and restoration of spermatogenesis on day 20 and 60 after application.

MATERIAL AND METHODS

Our experiments was carried out on eight (n=8) 8-month old boars of Slovak large white breed. For 100 days the animals were fed only barley meal and had free access to drinking water. Before inclusion in the experiment, all animals were examined for serum zinc level by the method of atomic absorption spectrophotometry using a flame absorption spectrophotometer Perkin Elmer, type 100. Two boars were castrated (n=2) and testes samples were taken for histological examination. Six experimental boars (n=6) with hypozincaemia were administered intramuscularly Zindep[®] in a dose of 0.2 mgZn/kg body weight. Additional three boars were castrated on day 20 and the last three animals on day 60 after treatment. Samples of blood were taken before castration and the animals were examined for serum zinc concentration.

Samples of the testes for light microscopy (LM) were processed routinely. They were fixed in 4 % neutral formaldehyde, embedded in paraffin, and the sections were stained with haematoxylin-eosin and examined under Jenamed light microscope.

Excisions for transmission electron microscopy (TEM) were fixed by immersion in 3% glutaraldehyde, postfixed in 1% OsO₄ (both in phosphate buffer pH 7.2-7.4), dehydrated in acetone and propylene oxide, and embedded in Durcupan ACM (Fluka). The ultrathin sections were cut on the ultramicrotome LKB Nova, double contrasted using uranylacetate and lead citrate and examined by the Tesla BS 500 electron microscope. The semithin sections processed for electron microscopy were stained with toluidine blue and examined under a light microscope.

RESULTS

Biochemical analyses

Zinc serum levels in boars before the experiment reached $20.10 \pm 1.72 \mu\text{M}$. After 100 days of feeding barley meal the zinc level was $8.97 \pm 1.65 \mu\text{M}$ which indicated a marked hypozincaemia. By day 20 after administration of preparation Zindep® inj. the level of zinc increased to $22.13 \pm 1.45 \mu\text{M}$ and by day 60 it showed a slight decrease to $18.46 \pm 1.056 \mu\text{M}$.

The concentration of zinc in the barley meal was 30.14 mg/kg.

Clinical examination of the skin

All boars fed barley meal for 100 days showed pronounced skin changes. The animals had pale, thickened, and dry skin with brittle hair, particularly around the ears, on the back and articular parts of the extremities. Favourable effects of the preparation Zindep® inj. were observed on day 20 after i.m. administration and on day 60 no skin problem could be detected although the feed rations remained unchanged.

Morphological examination of testes

Microscopic examination of the testes of boars before the experiment indicated normal spermatogenesis. The testes of boars with hypozincaemia showed marked changes in the seminiferous tubules which indicated spermatogenesis disorders. Cells of the seminiferous epithelium degenerated and were depleted. Seminiferous tubules were shrivelled and free spaces could be observed in the interstitium (Figure 1). Walls of seminiferous tubules were undulated and some Sertoli cells and cells of the seminiferous epithelium were

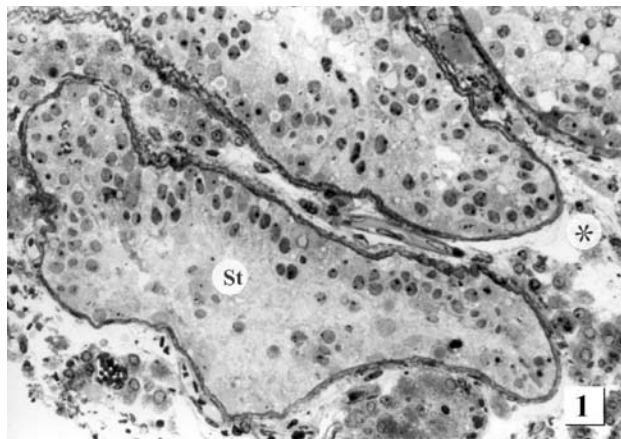


Figure 1. The section of seminiferous tubules – zinc deficiency (semithin section). Spermatogenesis is disturbed considerably, the seminiferous tubules (St) are shrivelled and the interstitium contains free spaces (asterix) (400 x)

damaged (Figure 2). Transmission electron microscopy confirmed the light microscopy results. The *lamina basalis* was layered and pronouncedly undulated. In the cytoplasm of Sertoli cells vacuoles were present. The nucleus near by the *lamina basalis* had diffusely scattered chromatin and the nuclear membrane formed numerous invaginations. Some cells of the seminiferous epithelium were degenerated (Figure 3).

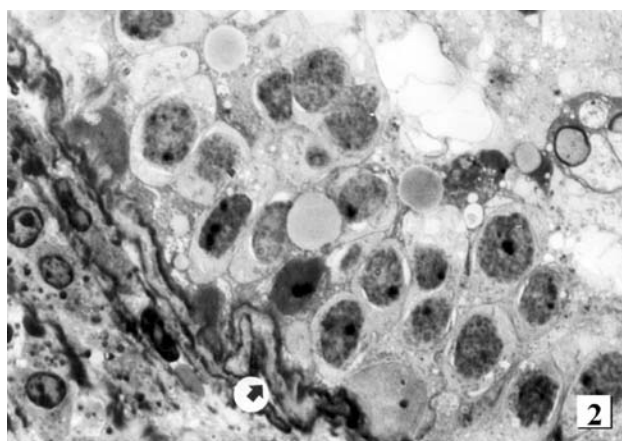


Figure 2. The cross section of a seminiferous tubule - zinc deficiency (semithin section). The wall of the seminiferous tubules is undulated (arrow), Sertoli cells and cells of the seminiferous epithelium are damaged (1 000 x)

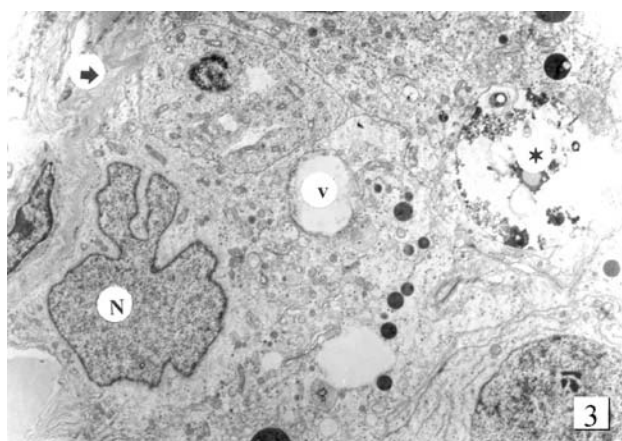


Figure 3. Part of the seminiferous tubule – zinc deficiency (electron micrograph). The *lamina basalis* is layered and undulated (arrow). In the Sertoli cells cytoplasm vacuoles (v) are present. The nucleus (N) contains diffusely scattered chromatin and the nuclear membrane forms numerous invaginations. Some cells of the seminiferous epithelium are degenerated (asterix) (10 000 x)

Changes were observed also in the interstitial tissue which contained Leydig cells that were located usually close to the blood vessels (Figure 4). Some

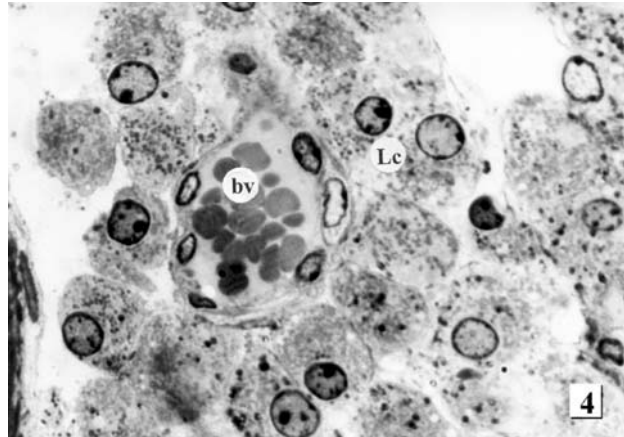


Figure 4. Interstitial tissue with Leydig cells - zinc deficiency (semithin section). Leydig cells (Lc) are commonly located close to blood vessels (bv). Some of the Leydig cells are damaged and disintegrated (1 000 x)

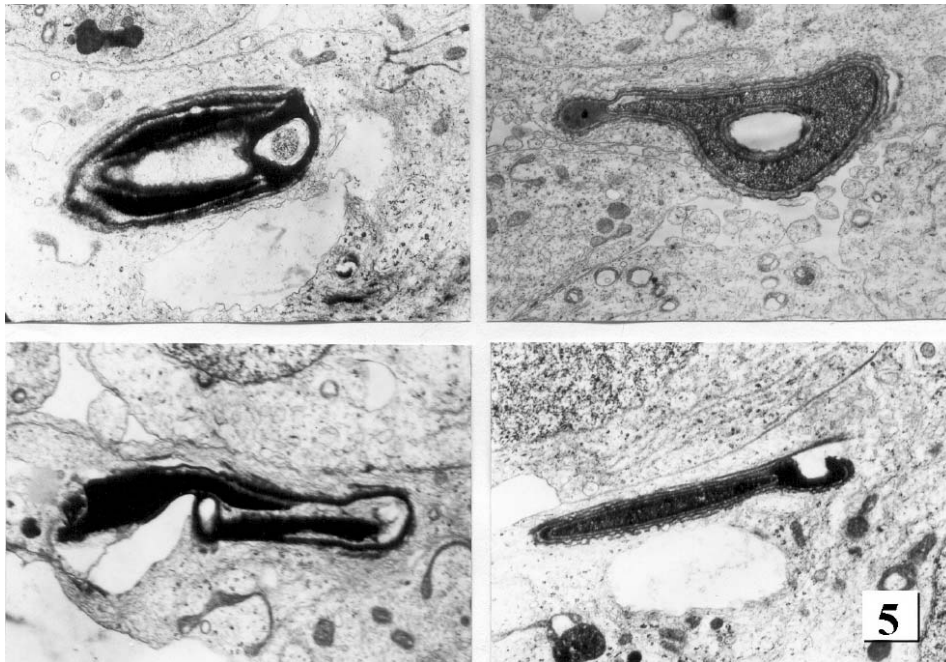


Figure 5. Electron micrographs of four malformed spermatids - zinc deficiency. (10 000 x)

Leydig cells were damaged and disintegrated. These changes indicated marked disorders in the production of testosterone. Electron microscope examination showed that in the seminiferous tubules was present a higher incidence of malformed spermatids, particularly in the last stage of maturation. Double headed spermatozoa, heads of various bizarre shapes, undulation of the cytoplasmic membrane and its invagination into the acrosome were evident (Figure 5).

On day 20 after Zn administration only partial, and on day 60 complete recovery of spermatogenesis was observed. The seminiferous tubules contained high seminiferous epithelium. Sertoli cells were not damaged and seminiferous tubules contained cells in the stage of mitosis, meiosis and metamorphosis (Figure 6). The interstitium contained a number of differentiated Leydig cells. In their cytoplasm there were a lot of smooth endoplasmic reticulum cisterns and mitochondria with tubules. This finding implies the synthesis of steroid hormones.

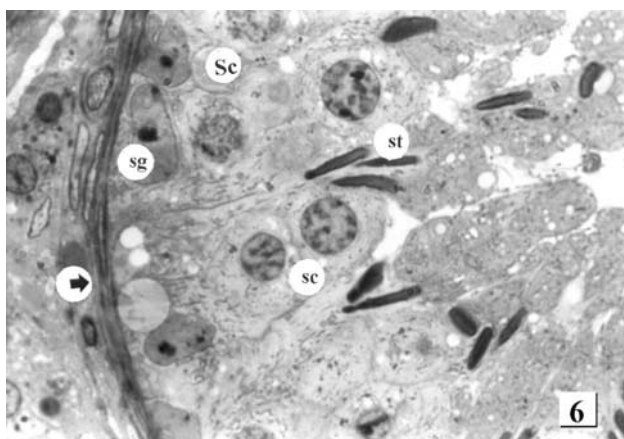


Figure 6. The cross section of a seminiferous tubule – day 60 after i.m. administration of Zn (semithin section). Spermatogenesis is normal. The walls of the seminiferous tubules are flat (arrow), Sertoli cells (Sc), spermatogonia (sg), spermatocytes (sc), and spermatids (st) show no signs of damage (1 000 x)

DISCUSSION

All boars which fed for 100 days only barley meal *ad libitum* and had free access to drinking water exhibited marked hypozincaemia. A single parenteral application of the preparation Zindep[®] inj. with elemental zinc and zinc oxide, into the neck muscles at the recommended dose of 0.2 mg/kg, caused no undesirable local changes. The effect of this preparation is long-lasting and zinc is absorbed into the blood gradually over a long period. If higher doses are required, they should be administered into several injection sites. After administration, the skin changes began to adjust back to normal and on day 20 a considerable

improvement was observed. The appetite of the animals was improved, as well. By day 60 after Zn administration the skin changes resolved completely.

Zinc is an element essential for normal spermatogenesis. Its deficit causes degenerative changes in spermatogenic cells and their subsequent depletion. The seminiferous tubules were shrivelled, the basal membrane undulated, and the cells of the seminiferous epithelium were damaged. Some Sertoli cells were degenerated while others were not markedly damaged.

Sertoli cells play a key role in the local regulation of spermatogenesis (Zibrín, *et al.*, 2005). However, spermatogonia A₀ were not damaged and after administration of zinc these stem cells could lead to recovery of the normal process of spermatogenesis. According to Ueda *et al.* (1991) zinc deficiency may prevent polymerisation of RNA and DNA in the testes.

Considerable changes were observed not only in the seminiferous tubules but also in the interstitium. Some Leydig cells degenerated and degenerative changes were observed in both the nucleus and cytoplasm. By day 60 after Zn administration, the structure of Leydig cells changed considerably. They had well developed cisternae of smooth endoplasmic reticulum and abundant mitochondria with tubulae mitochondriales. Such a structure of Leydig cells is typical of steroidogenesis (Zibrín, 1990). Biosynthesis of testosterone from cholesterol via pregnenolon takes place in the mitochondria and in the membranes of the smooth endoplasmic reticulum.

Zn deficiency was accompanied with increased occurrence of malformed spermatids. Our investigations agreed with the previous observations of hypozincaemia in bulls (Mesároš *et al.*, 1994) and stallions (Cigánková *et al.*, 1998), in which no skin lesions were observed, but keratin in stallions was of low quality.

Deficit of zinc in young growing pigs may result in parakeratosis, accompanied frequently with anorexia and growth disorders (Hesketh, 1982). The onset of clinical symptoms of zinc deficiency in pigs was observed when the serum levels of zinc ranged between 7 and 10 μ M (Bíreš and Vrzgula, 1988). If the zinc supply is optimal, the blood zinc level ranges 16 - 45 μ M. The daily demands of pigs in zinc are satisfied if the daily rations contain 50 mg Zn/kg d. m. (Georgijevskij *et al.*, 1982; Holden, 1987). Zinc deficiency causes lesions in the intestinal walls, calcification of the skin, and keratinisation disorders. The skin becomes thicker crackly and wrinkled and scabs are produced. Nutrition plays a very important role in maintaining the good health of individuals and, at the same time, has a favourable effect on reproductive functions (Massányi *et al.*, 1998; 2000). Mandelík *et al.* (2005; 2006) verified the efficiency of the Zindep[®]inj. preparation (Biotika, SR) with its prolonged effect at an insemination centre with cases of boars suffering from hypozincaemia. They observed that a single intramuscular administration at a dose recommended by the producer (10 mg Zn/kg b. w.) had a positive effect on the reproductive performance of boars. The preparation influenced significantly some quantitative and qualitative parameters of the boar semen, such as sperm concentration, total number of spermatozoa per ejaculation, the motility of spermatozoa after collection and the total number of morphologically abnormal spermatozoa.

After administration of zinc a partial recovery of spermatogenesis was observed on day 20 and complete recovery on day 60. Good tolerability and high biological effectiveness of the preparation was observed in boars not only with regard to spermatogenesis but also to favourable effects on the skin and improved appetite.

Address for correspondence:
Assoc. Prof. Viera Cigánková, DVM, PhD
Department of Anatomy, Histology and Physiology
University of Veterinary Medicine
Komenského 73
041 83 Košice, Slovak Republic
E-mail: cigankova@uvm.sk

REFERENCES

1. Bíreš J, Vrzgula L, 1985, Clinical and biological significance of zinc for ruminants, *Veterinářství* (In Slovak), 40, 42-4.
2. Bíreš J, Vrzgula L, 1988, Zinc as an immunomodulator in ruminants and pigs. *Veterinářství* (In Slovak), 35, 62-4.
3. Cigánková V, Mesároš P, Bíreš J, Ledecký V, Cigánek J, Tomajková E, 1998, Morphological changes of the testes in stallions at zinc deficiency, *Slov Vet J* (In Slovak), 23, 97-100.
4. Hesketh JE, 1982, Effects of dietary zinc deficiency on Leydig cell ultrastructure in boar, *J Comp Pathol*, 92, 239-247.
5. Georgijevskij VI, Annenkov BN, Samochin VT, 1982, *Mineral Nutrition of Animals*. Editors, Příroda, Bratislava, 431.
6. Holden P, 1987, Swine trace mineral requirements, *Agri Practice, Swine Nutrition*, 8, 14-6.
7. Mandelík R, Mesároš P, Cigánková V, Sviatko P, Valocký I, Hajurka J et al, 2005, Zinc and cooper concentration in the blood serum of boars after the administration of Zindep inj. a u v, *Folia Veter*, 49, 4, 193-7.
8. Mandelík R, Mesároš P, Cigánková V, Sviatko P, Valocký I, Hajurka J et al, 2006, Influence of parenteral administration of zinc on the reproductive performance of boars, *Folia Veter*, 50, 1, 28-32.
9. Massányi P, Trandžik J, Lukáč N, Strapák P, Kováčik J, Toman R, 2000, Contamination of bovine semen with cadmium, copper, lead, and zinc and its relation to the quality of spermatozoa used for insemination, *Folia Veter*, 44, 150-3.
10. Massányi P, Horniaková E, Lukáč N, Hustý S, 1998, Evaluation of breeding bull ejaculate quality in relation to the level of nutrition, *Agriculture*, 44, 589-99.
11. Mc Clain CJ, Gavaler JS, Van Thiel DH, 1984, Hypogonadism in the zinc - deficient rat: Localization of the functional abnormalities, *J Lab Clin Med*, 104, 1007-15.
12. Mesároš P, Bíreš J, Cigánková V, Černota S, Ravaszová O, 1994, Effect of the application of Zindep inj. on some biochemical and spermatological parameters of the bull ejaculate, *Slov Vet J* (In Slovak), 19, 3-6.
13. Mesároš P, Cigánková V, Bíreš J, Lukačinová M, 1999, Influence of the parenteral administration of zinc on the metabolism and seminal fluid of the ram, *Folia Veter*, 43, 9-12.
14. Ueda H, Kayama F, Mori N, Doi Y, Fujimoto S, 1991, Effects of dietary zinc deficiency on protein secretory functions of the mouse testis, *Arch Histol Cytol*, 54, 401-10.
15. Silvestroni A, Menditto A, Scarpa S, 1989, Zinc uptake in human seminal spermatozoa: Characterization and effects on cell membranes, *Arch Androl*, 23, 97-103.
16. Zibrín M, 1990, Male Reproductive System (In Slovak). In: Belák M et al., editors, *Veterinary Histology*, Příroda Bratislava, 331-68.

17. Zibrín M, Pivko J, Kačmárik J, Ciberej J, Tomajková E, 2005, Classification of cell structures: a functional approach demonstrated on Sertoli cell with a minireview on its structure and functions. *Biologia*, Bratislava, 60, 615-24.

MORFOLOŠKE PROMENE U TESTISIMA NERASTOVA SA DEFICITOM CINKA

CIGÁNKOVÁ VIERA, MESÁROŠ P, ALMÁŠIOVÁ VIERA i BÍREŠ J

SADRŽAJ

Cilj ovog rada je bio da se ispituju morfološke promene u testisima nerastova sa deficitom cinka izazvanim obrokom baziranom na ječmu. Ogled je izveden na osam nerastova Slovačke velike bele rase starih osam meseci. Tokom perioda od 100 dana, nerastovi su hranjeni samo ječmom i imali su slobodan pristup hrani i vodi. Pre uključivanja u ogled, svim jedinkama je određena koncentracija cinka u serumu atomskom spektrofotometrijom i dobijena je srednja vrednost od $20,10 \pm 1,72 \mu\text{M}$. Nakon 100 dana ishrane ječmom srednja vrednost je iznosila $8,97 \pm 1,65 \mu\text{M}$ što je ukazivalo na deficit cinka. Dvadeset dana nakon administracije preparata Zindep inj. (Biotika, SR), koncentracija cinka u serumu se povećala na $22,13 \pm 1,45 \mu\text{M}$ a 60. dana se smanjila na $18,46 \pm 1,056 \mu\text{M}$. Koncentracija cinka u ječmu je bila $30,14 \text{ mg} \cdot \text{kg}^{-1}$. Deficit cinka je dovodio do neujednačene degeneracije i deplecije ćelija semenog epitela i morfoloških promena na Sertoli ćelijama. Morfološke promene su takođe primećene na Leydig-ovim ćelijama i broj spermataida sa malformacijama je bio povećan. Deficit cinka je bio praćen sa anoreksijom, poremećajima rasta i parakeratozom. Jednokratna aplikacija preparata Zindep inj. u dozi od $0,2 \text{ mg Zn} \cdot \text{kg}^{-1}$ telesne mase dovela je do delimičnog korigovanja spermatogeneze a sa 60 dana oporavak je bio potpun.