

ASCARIDIA GALLI INFECTION IN LAYING HENS AND THE RESULTS OF *IN VITRO* EFFICACY OF LEVAMISOLE, PIPERAZINE AND CARVACROL, WHETHER IS NECESSARY TO CHANGE THE DEWORMING PROTOCOLS?

RAJKOVIĆ Milan^{1,5}, VUČIĆEVIĆ Ivana², VUČIĆEVIĆ Miloš³, DOŠENOVIĆ Milan³, CHARVET L. Claude⁴, RESANOVIĆ Radmila³, TRAILOVIĆ M. Saša^{5*}

¹Department of Biology, Faculty of Veterinary Medicine, University of Belgrade, 11000 Belgrade;

²Department of Pathology, Faculty of Veterinary Medicine, University of Belgrade, 11000 Belgrade;

³Department of equine, small animal, poultry and wild animal diseases, Faculty of Veterinary Medicine, University of Belgrade, 11000 Belgrade; ⁴ISP, INRA, Université Tours, UMR1282, 37380, Nouzilly, France; ⁵Department of Pharmacology and Toxicology, Faculty of Veterinary Medicine, University of Belgrade, 11000 Belgrade

(Received 01 November, Accepted 29 November 2019)

We present a case of *Ascaridia galli* infection in laying hens on a farm in central Serbia. During the rearing period on litter, ascariidosis was diagnosed at 15 weeks of age by routine parasitological fecal examination. Pullets were treated with flubendazole for one week, and two weeks later the hens were moved to battery cages. The production results were within technological standards until the 23rd week and the medical health status was without any clinical symptoms. After that period weight loss began, the egg production dropped to 70% and eggs were of poor quality. Subsequently, severe feather pecking and an increase of mortality were reported. The postmortal examination showed severe anemia and several gross lesions in the liver, intestines, lungs, and kidneys. Different sizes of *A. galli* were found in the lumen of the duodenum and jejunum. Gross changes of the intestinal mucosa were present, such as a thickened intestinal wall with hemorrhagic spots, inflammation and necrotic patches. Histopathological examination showed marked changes in the intestines, liver and kidneys. All visible live parasites were collected and stored in Earle's balanced salts, and females were used for *in vitro* susceptibility testing. Median lethal concentration (LC₅₀) of piperazine, levamisole and carvacrol for *A. galli* was 119.7µM, 2.71µM and 3.26µM, were applied, respectively. Based on our results, it is likely that reinfection occurred after completed dehelminthization. In relation to the new circumstances and the regulation for laying hen welfare the deworming protocol should be changed in order to ensure successful dehelminthization. In order to prevent reinfection the treatment must be done at the end of the rearing period and thus be maximally effective.

Keywords: *A. galli*, levamisole, piperazine, carvacrol, laying hens

*Corresponding author: e-mail: sasa@vet.bg.ac.rs

INTRODUCTION

Based on the data published by FAO parasitic diseases continue to be of great importance in poultry production. These diseases occur primarily in deep-litter and free-range commercial systems. In traditional systems throughout the world a number of parasites are widely distributed and contribute significantly to low productivity. The most commonly mentioned are *Eimeria* spp., *Ascaridia galli* and *Heterakis gallinarum*, which is mainly due to the many studies carried out on these parasites. Based on published data, the prevalence of *A. galli* in Africa, Asia, Americas and Europe is 66.7, 60.5, 90.0 and 63.8 %, respectively [1]. In Europe the incidence of infection of hens with *A. galli* has increased dramatically after the EU banned conventional battery cages in 2012 [2]. *A. galli* is the largest nematode in poultry, belongs to the phylum Nematoda, and occurs worldwide in galliform birds of all ages. *Ascaridia galli* has a direct life cycle and the most common way of transmission is the fecal-oral route. The adults are present in the small intestine and their eggs show a high level of resilience and once they enter a certain habitat it can be very challenging to eradicate them completely [3]. Infection with *A. galli* causes reduction in growth rate and weight loss [4,5]. This may be related to damage of the intestinal mucosa, leading to loss of blood and, probably, secondary infections [6]. The severity of the intestinal lesions may depend on the number of worms established in the intestine [4]. The primary damage reduces the efficiency of feed utilization, but death has been observed in severe infections. Behavioral changes are also present and they are manifested as ground pecking, feather pecking (from moderate to severe) and social rank disruption [7]. Reduced egg production and weight loss are common symptoms. As *A. galli* has a direct life cycle infection can spread very fast, especially in the deep litter system.

There are two major problems in the prevention and treatment of ascariidiasis in poultry. First, the increasing level of resistance to anthelmintics and second, a limited number of anthelmintics that can be used in laying hens. Anthelmintic resistance is defined as a significant increase in the ability of individuals within a strain of parasites to tolerate doses of a compound which would prove lethal to the majority of individuals in a normal population of the same species [1]. Unfortunately, specific data about the resistance of *A. galli* does not exist, however clear indications of weaker effects of the antinematodal therapy can be found. In addition to resistance, the cause of the failure of anthelmintic therapy in poultry can also be a rapid reinfection. The period of protection after administration of the anthelmintic drug is very short, and the presence of parasite eggs in the litter easily causes reinfection.

In this paper we have described the case of natural infection of laying hens with *A. galli* and *in vitro* susceptibility of this nematode to some antinematodal drugs and carvacrol, the active ingredient of the essential oil of oregano and thyme, with a proven anthelmintic property [8,9].

MATERIALS AND METHODS

The infection was diagnosed in commercial laying hens (Lohmann Classic Brown) on a farm in central Serbia. During the rearing period on litter, ascaridosis was diagnosed at 15 weeks of age by routine parasitological fecal examination. Pullets were treated with flubendazole (Biovermin, Krka, Slovenia) according to the manufacturer's instructions, for one week. Thereafter, the rearing period was finished two weeks later and hens were moved to battery cages. The production results of laying hens until the 23rd week was within technological standards, while the medical condition was completely normal, without any clinical symptoms. After that period the birds began losing weight, egg production dropped to 70% and lower egg quality was also present. Subsequently, severe feather pecking and increased mortality were reported. In a facility with 10000 hens, mortality increased from 60, on the 23rd week to 150 individuals at 30 weeks of age, and remained on the same level further on. Autopsies during that period showed cachexia, necrotic enteritis and wounds on the lumbar part of the body.

Immediately after death, the hens were brought to the Department of Pathology, Faculty of Veterinary Medicine in Belgrade. Necropsy for this investigation was performed on 20 hens, 35 weeks old. At the beginning all hens were examined for gross lesions. Furthermore, for histopathological examination, the intestinal, liver, kidney and lung tissues were sampled and fixed in 10% neutral buffered formalin and processed routinely. Paraffin-embedded sections were cut at 4 μm thick tissue sections which were stained with hematoxylin and eosin (HE) and Periodic Acid Schiff (PAS), and analyzed under a light microscope (BX51, Olympus Optical, Japan). Digital images were made using an optical microscope Olympus BX51 with digital camera Olympus Color View III.

After opening the intestines, live nematodes were taken and transferred to tempered glass beakers filled with Earle's balanced salts (EBSS, composition in mM: NaCl 116, CaCl_2 1.8, MgSO_4 0.8, KCl 5.4, NaH_2PO_4 1.0, Phenol Red·Na 0.003, pH 7.6 with NaOH, 3 mM glucose at 42°C) for up to 72 h. Worms were examined under a light microscope and identified based on morphological keys according to Soulsby [5] and Norton and Ruff [10], and males and females were measured for length using a ruler.

For the *in vitro* susceptibility studies, adult females of *A. galli* were used. Solutions of increasing concentrations of carvacrol (0.3, 1, 3, 10, 30, and 100 μM), piperazine (3, 10, 30, 100, 300, and 1000 μM) and levamisole (0.3, 1, 3, 10, 30, and 100 μM) were prepared.

Carvacrol was dissolved in ethanol, with a final concentration of ethanol in the Earle's salts of 0.1 %v/v. Levamisole was dissolved in DMSO such that the final DMSO concentration in the Earle's salts did not exceed 0.1% v/v, while piperazine was dissolved in Earle's salts.

Glass beakers, each with 50 ml of tested concentrations of carvacrol, piperazine or levamisole, were placed in a water bath with a movable bottom, at 41°C. Six live *A. galli* females were added to each beaker. Additionally, three beakers served as controls, the first with 0.1% ethanol in Earle's salts, the second with 0.1% DMSO in Earle's salts and the third with 50ml pure Earle's salts. Six live *A. galli* females were placed in each of the control beakers.

After 60 minutes of incubation, the number of live and dead worms was determined in each beaker. The data obtained were used to calculate the mean lethal concentration of the tested substances.

Drugs and chemicals

Carvacrol, levamisole and piperazine were obtained from Sigma-Aldrich Co (St Louis, MO, USA).

Statistical analysis

The median lethal concentrations (LC_{50}) of carvacrol, levamisole and piperazine for *A. galli* was calculated by non-linear regression. Prism 5.0 (GraphPad Software, San Diego, CA.) was used to estimate the LC_{50} .

RESULTS

Examination of the dead hens revealed severe anemia and various gross lesions in the liver, intestines, lungs, and kidneys. Different sizes of *A. galli* were found in the lumen of the duodenum and jejunum, and they were collected for identification and further pharmacological research. Gross changes of the intestinal mucosa showed a thickened intestinal wall with hemorrhagic spots, inflammation and necrotic patches. The surface of the intestinal mucosa was covered with mucous. Postmortem examination of the liver showed dark red coloration in most cases, while some chickens had a pale and discolored liver. Kidneys were edematous and pale with greyish spots in the cortex. Dark red and moist areas of skin devoid of feathers were visible on the lateral sides of the pelvis and thighs. Skin patches were missing and the subcutaneous tissue was affected by necrotic changes mainly on the back.

Histopathological examination of the intestine sections showed the parasites in the lumen (Figure 1A). Desquamation and adhesion of the mucosal villi, degeneration and necrosis of the epithelial cells were evident, as well as intestinal hyperemia (Figure 1B and Figure 1C). Microscopical examination of the intestines also revealed a large number of mucin producing goblet cells (Figure 1D). The mucosal layer was infiltrated mainly with mononuclear cells around the necrotic areas with a small number of heterophils and eosinophils.

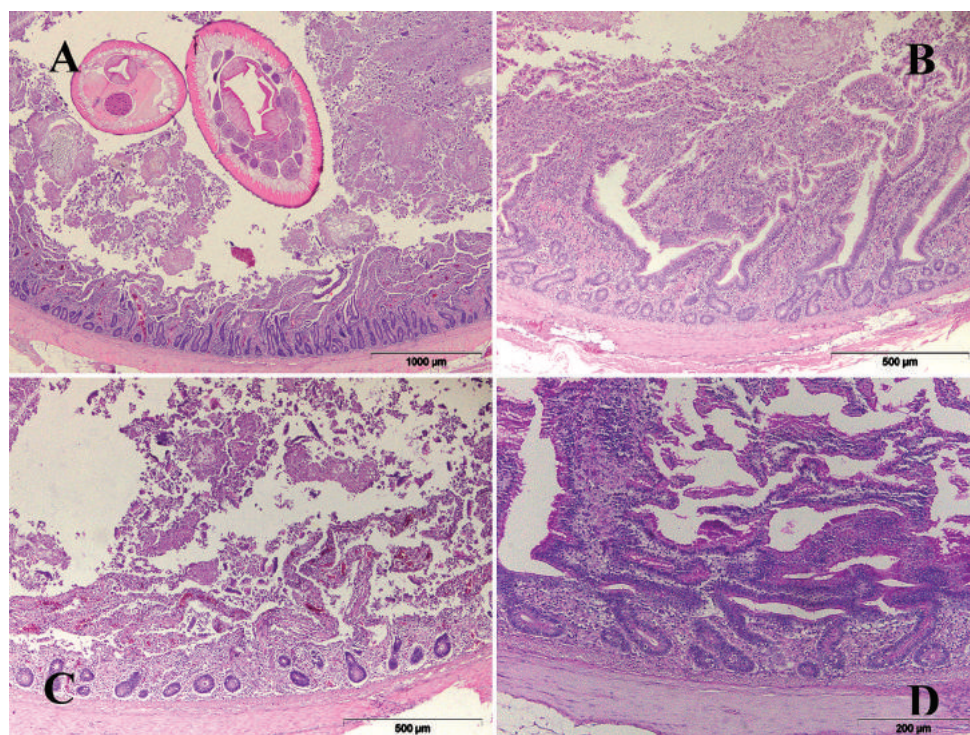


Figure 1. Histological characteristics of the small intestine of laying hens naturally infected with *Ascaridia galli*. **A)** Cross-sections of *A. galli* in the lumen of the intestine, HE; **B)** Villi fusion, HE; **C)** Necrosis of the epithelial cells and intestinal hyperemia, HE; **D)** Numerous mucin-producing goblet cells, PAS.

The microscopical examination of the liver showed inflammatory cell infiltrate around the portal veins, mainly consisted of mononuclear cells and subcapsular hemorrhage. The liver of some infected birds disclosed a fatty degeneration. The major histological changes related to the kidneys were interstitial edema and degenerative changes present in the tubular epithelium, mainly associated with an intense cell infiltration of the interstitium which consisted of lymphocytes and macrophages (multifocal interstitial nephritis).

A. galli males were 39-51 mm long and the females were 58-79 mm. For the pharmacological investigations a total of 108 female *A. galli* were divided into 18 experimental groups. To each bottle with 50 ml of Earle's balanced salts and one of the tested substances, 6 females were placed, while three groups (6 worms each) were the control (without test substance). The effect of increasing concentrations of the tested substances was evaluated based on the presence or absence of movement of worms after 60 minutes of incubation in a water bath at 41°C.

Results of testing *in vitro* susceptibility of the adult female *A. galli*, showed that the median lethal concentration (LC_{50}) of piperazine was 119.7 μ M ($\log LC_{50} \pm SE =$

2.078±0.078) with 95% Confidence Intervals 75.20 to 190.5 μM (Figure 2). The value of median lethal concentration (LC_{50}) of levamisole for *A. galli* was 2.71 μM ($\log\text{LC}_{50}\pm\text{SE}=0.433\pm0.089$), with 95% Confidence Intervals 1.597 to 4.610 μM (Figure 3). At the end of this study we determined the LC_{50} of carvacrol, which amounted 3.26mM ($\log\text{LC}_{50}\pm\text{SE}=0.514\pm0.165$), with 95% Confidence Intervals 1.225 to 8.682 μM (Figure 4). In the control group there was no lethality, after 60 minutes of incubation.

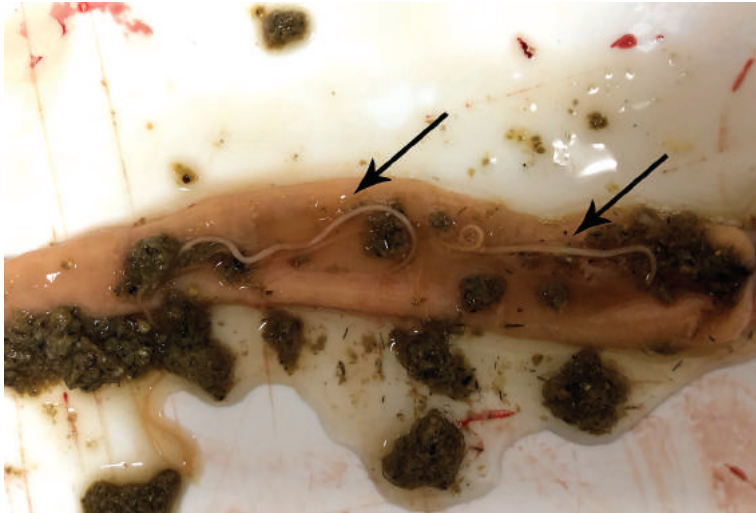


Figure 2. Adult *A. galli* (indicated by arrows) in the small intestine of laying hens.

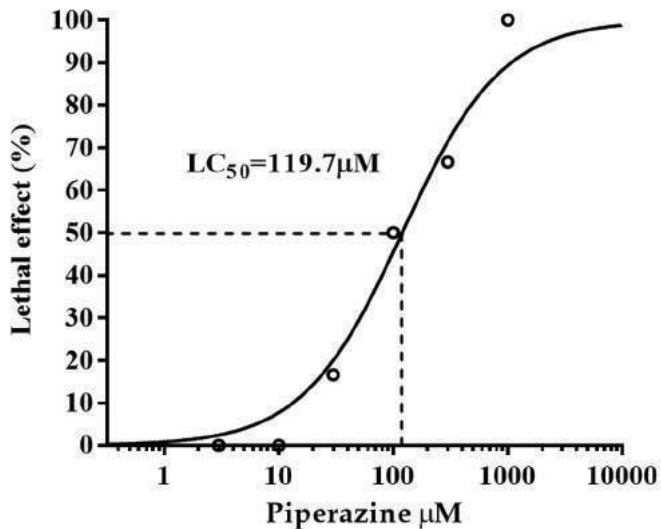


Figure 3. The median lethal concentration (LC_{50}) of piperazine for the female *A. galli*.

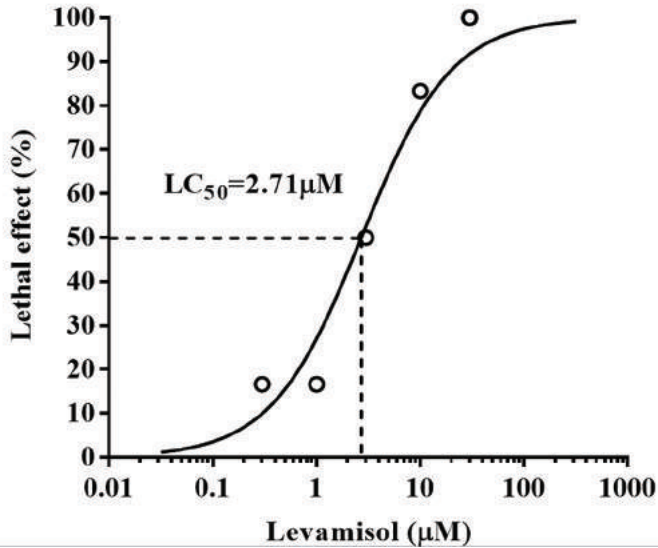


Figure 4. The median lethal concentration (LC_{50}) of levamisole for the female *A. galli*.

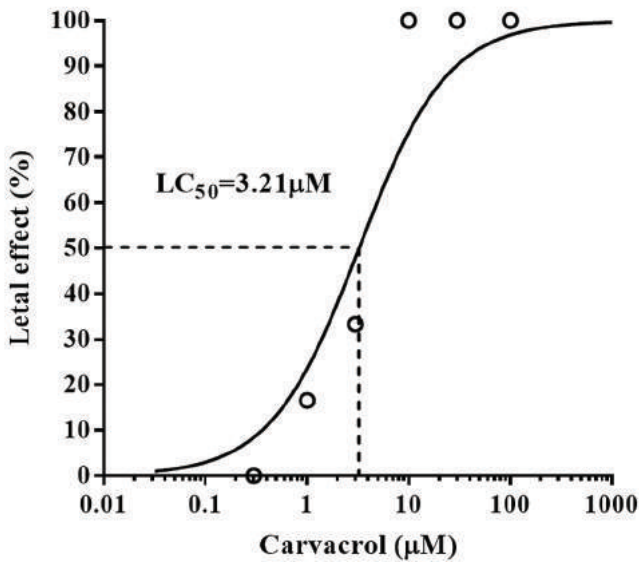


Figure 5. The median lethal concentration (LC_{50}) of carvacrol for the female *A. galli*.

DISCUSSION

A. galli is the most common nematode in poultry [6,11], having a direct life cycle in the intestinal tract with a larval migratory phase into the enteric wall [13]. Penetration of the parasite into the small intestine mucosa may cause hemorrhagic to necrotic enteritis, associated with anemia and diarrhea [14]. In our study, gross changes observed in the

examined chickens included a pasty mucus in the lumen of duodenum and jejunum, thickened wall, hemorrhages and necrotic patches that were similar to changes caused by the presence of a moderate number of parasites [15,16]. Salam [15] found that parasites present in a small number do not cause macroscopically visible changes, while moderate infection is associated with mucous enteritis. Balqis et al. [14] have shown that the presence of *A. galli* leads to epithelial desquamation of the duodenal villi, hyperplasia of small intestinal villi, and fusion of all jejunal and ileal villi and 90% of duodenal villi. According to Prastowo et al. [17] infection with *A. galli* leads to an increase in the number of goblet cells which was also observed in our study. Mucus produced by goblet cells covers the surface of the small intestine and has a very important role in stimulating an immune response of the mucous membrane. Some other authors have described changes in the liver of infected birds. In addition to the reported pathological changes in the chicken intestine, Adang et al. [18] reported fatty degeneration with coagulation necrosis of pigeon liver. Fatty changes were also present in some chicken livers from our study. More severe microscopical changes revealed diffused hemorrhage and focal necrosis were described by Bsrat et al. [19]. These changes indicate that the infection with *A. galli* results in serious pathological changes that are responsible not only for the reduction in production capacity, but already have been the cause of a large number of deaths of laying hens.

At this point arises the question about the effectiveness of the treatment that was conducted in the 15th week of the rearing period. Unfortunately, it is obvious that the therapy was unsuccessful. The reason for complete absence of effects of therapy may be the resistance of parasites to flubendazole or the reinfection that followed after the cessation of treatment. Unfortunately, we were not able to test the *in vitro* susceptibility of *A. galli* to flubendazole, but we have examined the effectiveness of levamisole, piperazine and carvacrol. In our study, levamisole exhibits a high efficacy against *A. galli*, with a value of $LC_{50}=2.71\mu\text{M}$. Almamy et al. [20] have published that 0.5mg/ml of levamisole kills all tested *A. galli in vitro*, which is a much higher concentration compared to the LC_{50} determined in our study. Also, the obtained LC_{50} value is much lower than the concentration of levamisole (10 μM) that induced a strong depolarization of the muscle cells of *A. suum* in our previous electrophysiological investigations [21]. The LC_{50} of piperazine for *A. galli* in the presented study was 119.7 μM , which is consistent with the data published by Lalchandama [22]. This author reports that piperazine in concentrations of 10 to 230 μM effectively kills *A. galli in vitro* and that only differs in the survival time. In our earlier studies, piperazine at a concentration of 300 μM inhibited contractions of *A. suum* induced by acetylcholine [21]. Particularly interesting is the finding of the effect of carvacrol on *A. galli*. In our study LC_{50} of carvacrol against *A. galli* was 3.26 μM . There are no data related *in vitro* effectiveness of carvacrol against *A. galli*, but in the earlier trials we determined the LC_{50} of carvacrol for *C. elegans* is 57.03nM [9]. Furthermore, in the investigations of *A. suum* contractility, carvacrol effectively inhibited the acetylcholine-induced contractions in the concentration of 100 and 300 μM [8]. Based on the presented

comparative data, we can conclude that *A. galli* is sensitive to the tested drugs and that there is no evidence of the development of resistance. We unfortunately did not verify *in vitro* the susceptibility of *A. galli* to fenbendazol, which would certainly confirm the statement that resistance does not exist yet. This is why we can only assume that the presence of *A. galli* in hens after deworming is probably due to reinfection, which occurred in the period while the hens were on deep litter before moving into cages. According to the data of Tarbat [23], layers may be reinfected with *A. galli* over a week after the treatment with flubendazole.

Our findings show that infection with *A. galli* in hens has resulted in serious pathological damages and huge economic losses. Keeping hens in battery cages for many years resulted in a significant reduction in ascarid infection since the hens were separated from the feces, and therefore from the source of infection [24]. In the very near future, Serbia will face major animal husbandry changes due to the implementation of the laying hen welfare regulations laid down in the National Regulation and European Council Directive 99/74/EC. The new circumstances can bring new problems in poultry production. Deworming protocols should be changed in order to ensure successful dehelminthization. The treatment must be at the end of the rearing period and maximally effective, then it is necessary to prevent reinfection. One possibility could be the use of active ingredients of essential oils, which may be continuously applied and combined with classical anthelmintics.

Acknowledgments

This study was supported by the Ministry of Education and Science Republic of Serbia, Grant No TR31087 and the Serbia-France bilateral cooperation Hubert Curien Partnerships (Pavle Savic 2017 program No 40879QA and No 451-03-01963/2017-09/02).

Authors' contributions:

All authors participated in the design of the study, performed the statistical analysis, conceived of the study, and participated in its design and coordination and helped to draft the manuscript. All authors read and approved the final manuscript.

Declaration of conflicting interests:

The author(s) declared no potential conflicts of interest with respect to the research, authorship, and/or publication of this article.

REFERENCES

1. Permin A, Hansen JW: Epidemiology, diagnosis and control of poultry parasites. FAO Animal Health Manual N° 4, 1998.
2. Council Directive 1999/74/EC of 19 July 1999 laying down minimum standards for the protection of laying hens.
3. Sharma N, Hunt PW, Hine BC, Sharma NK, Chung A, Swick RA, Ruhnke I: Performance, egg quality, and liver lipid reserves of free-range laying hens naturally infected with *Ascaridia galli*. *Poult Sci.* 2018, 97(6): 1914-1921.
4. Soulsby EJJ: Helminths, Arthropods and Protozoa of Domesticated Animals. 7th ed. Baillier Tindall: Elsevier, 1982.
5. Ikeme MM: Observations on the pathogenicity and pathology of *Ascaridia galli*. *Parasitology* 1971, 63(2): 169-179.
6. Ackert JE, Herrick CA: Effects of the nematode *Ascaridia lineata* (Schneider) on growing chickens. *J Parasitol.* 1928, 15(1): 1-13.
7. Gauly M, Duss C, Erhardt G: Influence of *Ascaridia galli* infections and anthelmintic treatments on the behaviour and social ranks of laying hens (*Gallus gallus domesticus*). *Vet Parasitol.* 2009, 146(3-4): 271-280.
8. Trailović SM, Marjanović DS, Nedeljković Trailović J, Robertson AP, Martin RJ: Interaction of carvacrol with the *Ascaris suum* nicotinic acetylcholine receptors and gamma-aminobutyric acid receptors, potential mechanism of antinematodal action. *Parasitol Res.* 2015, 114(8): 3059-3068.
9. Marjanović SDj, Bogunović D, Milovanović M, Marinković D, Zdravković N: Antihelmintic activity of Carvacrol, Thymol, Cinnamaldehyde and P-Cymer against the free living nematode *Caenorhabditis elegans* and rat pinworm *Syphacia muris*. *Acta Vet-Beograd* 2018, 68(4): 445-456.
10. Norton RA, Ruff MD: Nematodes and Acanthocephalans. In: Saif YM, Barnes HJ, Glisson JR, Fadly AM, McDougald LR, Swayne DE (Eds): *Diseases of Poultry*. 11th edition. Iowa State Press, a Blackwell Publishing Company, Ames, Iowa. pp. 931-961.
11. Katakam K, Nejsum P, Kyvsgaard N, Jorgensen C, Thamsborg SM: Molecular and parasitological tools for the study of *Ascaridia galli* population dynamics in chickens. *Avian Pathol* 2010, 39: 81-85.
12. Ackert JE: The morphology and life history of the fowl nematode *Ascaridia lineata* (Schneider). *Parasitology* 1931, 23: 360-379.
13. Permin A, Bojesen M, Nansen P, Bisgaard M, Frandsen F, Pearman M: *Ascaridia galli* populations in chickens following single infections with different dose levels. *Parasitol Res.* 1997, 83(6): 614-617.
14. Balqis U, Hambal M, Darmawi, Cut S. Utami: Histopathological changes in intestine of chicken (*Gallus domesticus*) infected naturally by *Ascaridia galli*. *Proceedings of the 3rd Annual International Conference Syiah Kuala University (AIC Unsyiah)* 2013, 343-348.
15. Salam ST: Research article ascariasis in backyard chicken – prevalence, pathology and control. *Int J Recent Sci Res.* 2015, 6(4): 3361-3365.
16. Feroza S, Arijio AG, Bilqees FM, Phulan MS: *Ascaridia galli* infection induced gross-pathological changes in broiler chicken. *Pak J Nematol.* 2018, 36(2): 211-216.

17. Prastowo J, Herawati O, Ariyadi B, Kurniasih K: Effects of Areca catechu Seed and Anredera cordifolia Leaf on Ascaridia galli Infection in the Domestic Chicken (*Gallus gallus domesticus*). Int J Poult Sci 2017, 16(12): 494-499.
18. Adang KL, Abdu PA, Ajanusi JO, Oniye SJ, Ezealor AU: Histopathology of *Ascaridia galli* infection on liver, lung, intestine, Heart and kidney of Experimentally infected Domestic pigeons (*C.I.domestica*) in Zaria, Nigeria. J Sci Technol. 2010, 11: 511-515.
19. Bsrat A, Tesfay T, Tekle Y: Clinical, Gross and Histopathological Study on Common Local Chicken Diseases in Enderta District, South East Tigray. Eur J Biol Sci. 2014, 6(4): 95-103.
20. Almamy K, Mohamed BB, Adama K, Aristide T, Kessoum K, Hamidou HT: In vitro anthelmintic activity of *Securidaca longepedunculata* fresen. (polygalaceae) aqueous root bark extract against *Ascaridia galli* and *Raillietina echinobothrida* adult worms from guinea fowl (*Numida meleagris*). World J Pharm Res. 2017, 6(1): 31-40.
21. Trailovic SM, Robertson AP, Clark CL, Martin RJ. Levamisole receptor phosphorylation: effects of kinase antagonists on membrane potential responses in *Ascaris suum* suggest that CaM kinase and tyrosine kinase regulate sensitivity to levamisole. J Exp Biol. 2002, 205(24): 3979-3988.
22. Lalchandama L: Nematocidal effects of piperazine and the extract of *Acacia oxyphylla* stem bark on the poultry nematode, *Ascaridia galli*. Pharmacologyonline 2008, 3: 864-869.
23. Tarbiat B: *Ascaridia galli* in laying hens: Adaptation of a targeted treatment strategy with attention to anthelmintic resistance. Doctoral thesis Swedish University of Agricultural Sciences Uppsala 2018.
24. Jansson DS, Nyman A, Vagsholm I, Christensson D, Goransson M, Fossum O, Högglund J: *Ascarid* infections in laying hens kept in different housing systems, Avian Pathol. 2010, 39(6): 525-532.

ASCARIDIA GALLI INFEKCIJA KOD NOSILJA I REZULTATI IN VITRO EFIKASNOSTI LEVAMIZOLA, PIPERAZINA I KARVAKROLA, DA LI JE NEOPHODNO MENJATI PROTOKOLE DEHELMINTIZACIJE?

RAJKOVIĆ Milan, VUČIĆEVIĆ Ivana, VUČIĆEVIĆ Miloš, DOŠENOVIĆ Milan, CHARVET L. Claude, RESANOVIĆ Radmila, TRAILOVIĆ M. Saša

U ovom radu prikazujemo slučaj infekcije koka nosilja sa *Ascaridia galli* na jednoj farmi u centralnoj Srbiji. Tokom perioda odgoja na dubokoj prostirci, rutinskim parazitološkim pregledom fecesa dijagnostikovana je askaridijaza u 15. nedelji starosti. Živina je tretirana flubendazolom, tokom jedne nedelje a dve nedelje kasnije premeštena je u kaveze za eksploataciju. Nosivost je bila u okviru tehnoloških standarda do 23. nedelje i nisu bili prisutni simptomi oboljenja. Posle tog perioda nosilje su počele da mršave, nosivost je opala na 70% a kvalitet jaja se pogoršao. Posle toga pojavilo se intezivno kljucanje perja i rastući mortalitet. Posmortalni pregled je pokazao intezivnu anemiju i različite lezije na jetri, crevima, plućima i bubrezima, kao i rane na koži lumbalnog dela

ledja. U lumenu duodenuma i jejunuma su pronađene *A. galli* različite veličine. Promene na intestinalnoj mukozi sastojale su se od zadebljanja sa hemoragičnim mrljama, inflamacijom i nekrotičnim mrljama. Histopatološko ispitivanje ukazalo je na intezivne patološke promene u crevima, jetri i bubrezima. Svi živi paraziti su prikupljeni i čuvani u Earle-ovom rastvoru a ženke su korišćene za *in vitro* ispitivanje osetljivosti na antinematodne lekove. Srednja letalna koncentracija (LC_{50}) piperazina, levimizola i karvakrola za *A. galli* bila je 119,7 μ M, 2,71 μ M odnosno 3,26 μ M. Na osnovu naših rezultata najverovatnije da je došlo do reinfekcije posle sprovedene dehelmintizacije zbog prisustva jaja u prostirci. U odnosu na nove okolnosti i regulative o dobrobiti nosilja, potrebno je promeniti protokole dehelmintizacije kako bi se obezbedio uspeh terapije. Tretman mora da bude na kraju perioda odgoja i maksimalno efikasan, a zatim je neophodno onemogućiti reinfekciju.