

**RADIOLOGICAL ASSESMENT OF APEX FORMATION FOLLOWING USE OF
HYDROXYAPATITE**

MARKOVIĆ D*, PETROVIĆ VANJA*, KRSTIĆ N**, LAZAREVIĆ-MACANOVIĆ MIRJANA **
and NIKOLIĆ ZORANA*

* School of Dentistry, Belgrade

** Faculty of Veterinary Medicine, Belgrade

(Received 6. September 2006)

The treatment of pulp in teeth with incomplete apex formation is still a clinical challenge. In addition to the most widely used medication for this purpose, calcium hydroxide, other materials have also been tested. Following the use of synthetic biomaterials for restoring bone tissue, and considering their recognized biocompatibility and bioconductivity, our intention was to explore the possibility of using synthetic biomaterials in the endodontic treatment of permanent teeth with incomplete apex formation.

The aim of this study was to observe the effectiveness of hydroxyapatite in apexogenesis of young permanent teeth.

In this study a 100 µm synthetic hydroxyapatite material, Beohap (HAP) powder, was applied to 24 teeth in 3 dogs of 5.5 months of age, after incomplete root development was established on radiographs. The treated teeth were radiographed monthly and the radiographs compared with those of the corresponding teeth on the other side of the jaw until completion of apex growth. The tested teeth were divided into three groups according to the method of treatment: the first was direct pulp capping, the second was amputation of the pulp at the enamel-cement junction and the third was high amputation at the radiographically identified point of root growth.

On the basis of radiographic analysis, apex formation was successful in all test groups, with no significant differences between the three groups and the controls (Fisher's and χ^2 test). Deformities of the root apex were observed in two teeth (25%) in the third group.

Key words: apexogenesis, hydroxyapatite, endodontic treatment, radiography

INTRODUCTION

Root formation (apical development) has yet to be completed when teeth erupt in the mouth. Viewed on a dental radiograph, the root of a newly erupted human tooth is approximately two thirds of its final length. The root canal system

(pulp space) appears relatively large, with an apical diameter that is wider in the earlier stages of development than the diameter in the coronal and middle portions of its length and with thin and fragile dentinal walls. These anatomic characteristics are of significance to the clinician because of complications that can interfere with the completion of endodontic treatment, if necessary. The endodontic treatment of such teeth carries a poor prognosis and they also provide reduced support when a full crown restoration is required (Andreasen *et al.*, 2006).

The apical odontogenic complex consists of the dental pulp, dental follicle and Hertwig's epithelial root sheath. Injury to the tooth during its developmental stage can result in damage and functional failure of any or all of these tissues. The overall clinical effect of such injuries is proportional to the degree and extent of the damage of the odontogenic complex and the degree and extent to which repair occurs (Rafter, 2005). Considering the cellularity and vascularity of apical tissue in a developing tooth as compared to a fully developed tooth, the potential for recovery and repair subsequent to most injuries is good provided that no infection occurs (Torneck, 1982).

Apexification and apexogenesis are two endodontic procedures which attempt to either induce apical repair by initiating a hard tissue barrier across an open apex or to promote the continued formation of the apical portion of the root (Rafter, 2005). The success of apexogenesis depends on the integrity of the apical radicular pulp.

The use of calcium hydroxide pulpotomy has been widely applied and proved useful in the immediate treatment of exposed pulp in partially developed permanent teeth (Silva *et al.*, 2006; Accorinte *et al.*, 2006). To a greater or lesser extent dentine adhesives, bioceramic materials, MTA and materials of bioactive glass (Shabanshang and Torabinejad, 2000; Salako *et al.*, 2003; Rafter, 2005; Accorinte *et al.*, 2006) have been employed. Attempts to use enamel preparations (Emdogain) did not give the expected results in terms of forming a firm tissue barrier in exposed human pulp (Olsson *et al.*, 2005). Experiments are also directed towards testing the effects of various materials in combination with growth factors and growth factors themselves. (Thesleff and Vaahtokari, 1992; Tziafas *et al.*, 1992; Title *et al.*, 1996). When tricalcium phosphate was used to induce apical closure in human permanent pulpless teeth with large open apices, it was found to be no more effective than calcium hydroxide. (White and Goodis, 1991).

Synthetic hydroxyapatite belongs to the group of ceramic biomaterials with a wide range of use in medicine and dentistry. (Yamamuro and Hench 1990; Yamamuro and Wilson 1990). It is produced in two forms: non-porous and porous. It is also available in granules and cubes. The final morphology and stoichiometry of hydroxyapatite depend on how it was synthesized. Numerous biocompatibility studies showed that all forms of hydroxyapatite are biocompatible. Hydroxyapatite does not induce a giant cell reaction, considerable inflammation or elevate serum Ca and P. It is biocompatible with macrophages, fibroblasts, osteoclasts, osteoblasts and periodontal ligament cells. (Orly *et al.*, 1989; Gregoire and Menanteau, 1990; Cassidy *et al.*, 1997; Markovic *et al.*, 2006).

In addition to being biocompatible, synthetic Ca-phosphates have an effect on the formation of the dentine bridge (Mehlich *et al.*, 1987; Alliot-Licht and Gregoire, 1994). Newly calcified tissue forms directly along the material without the zone of necrosis characteristic of Ca(OH)₂. There is an evident change of morphology in human fibroblasts that come into contact with Ca(OH)₂: a change in DNA synthesis, alkaline phosphatase activity and protein synthesis. In the same study fibroblasts phagocytosed HAP molecules of less than 10 µm and had the effect of altering DNA synthesis; however, it was emphasized that the fibroblasts were not in a phase of differentiation and therefore biocompatibility was never an issue. Molecules of Ca(OH)₂ and HAP firmly adhered to the cellular membrane.

Comparing the reaction of the pulp to HAP (Osteogen®, a porous, reabsorbable material based on hydroxyapatite with particles of 300-400 µm) and Dycal® (calcium hydroxide based liner) in lab animals (rats), it was noticed that new odontoblasts and dentine bridge formation appeared in both instances. It is interesting that the authors do not recommend the use of Osteogen® for pulp treating due to the possibility of calcification in the pulp that may impede endodontic treatment. They believe Osteogen's® slight acidity, pH=6.4, probably leads to calcification in the pulp (Jaber *et al.*, 1992).

In addition to the ceramic form of HAP, the cement form of HAP has been studied since 1991. It is produced by direct crystallization *in vivo* without heating to high temperatures in order to obtain a structurally stable implant. Applied during the procedure in the form of a paste, it becomes a structurally stable implant with a micro porous structure. (Cassidy *et al.*, 1997).

Recent studies of organic HAP obtained from eggshells for direct and indirect pulp capping have also given favourable results. (Djordjevic, 2004).

MATERIAL AND METHODS

The aim of this study was to examine apexogenesis in teeth with immature roots following the use of hydroxiapatite.

Tested material was synthetic hydroxyapatite, *Beohap*, powder with a particle size of 100 µm.

Methods: The procedure was performed on single root teeth with immature roots in three lab dogs of 5.5 months of age. The Animal Ethical Screening Comitee permission was obtained prior to the investigation. The presence of permanent teeth was confirmed before the experiment and the teeth proved to be in different stages of apex development (Figure 1). The tested teeth were divided into three groups of 8 teeth each.

I – In the first group direct pulp capping was performed. A small 0.5 mm area of pulp was exposed on the labial surfaces and the pulp was covered with HAP.

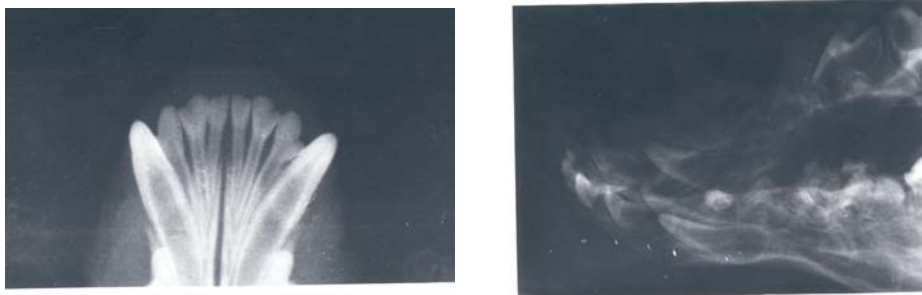
II – In the second group a vital amputation was performed at the cement-enamel junction and the wound was covered with HAP.

III – Teeth in the third group were given high amputations at the point of immature root growth identified on radiographs. The wound was covered with HAP and the root space obturated with Silapex and gutapercha.

All cavities were filled with glass ionomer cement liner and amalgam fillings. Radiographs were taken after the procedure and every month following until the completion of root growth.

Controls: Contralateral untreated teeth served as controls.

Monitoring and scoring: The following was monitored with the aid of radiographs: (a) presence of dentine bridge in treated teeth, (b) retardation of root growth compared to controls, (c) presence of deformations in the newly formed part of the apex, (d) any presence of pathology in the periapical region and obliteration of pulp space with the presence of denticles. Observed parameters were scored with 1 (yes) and 0 (no). Root growth was evaluated from radiographs. The evaluation of root growth was recorded by Demjrian's scale for dental maturity and tooth age determination (1973) from A to H (Figure 2). Root formation was considered "complete" (G,H) when the root apex was closed or near completion and the canal was tapering with near normal root length. Any other configurations of the root such as wide open (blunderbuss) apex, closed apex with wide elliptical canal, and shortened root with or without closed apex, were considered "incomplete" (A-F).



Figures 1a and b. The presence of permanent teeth in different stages of development

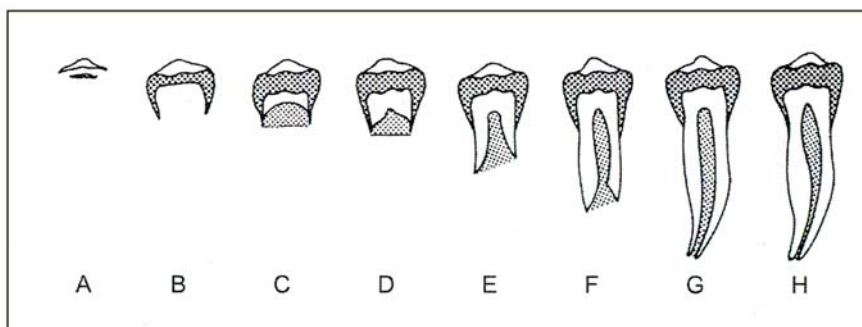


Figure 2. Demjrian's scale for dental growth and teeth mineralisation

RESULTS

Table 1. Group 1. Pulp capping with hydroxyapatite

Test teeth										Controls									
	Observed parameters				Stage of devel. at the beginning	Stage of devel. at the end	Observed parameters				Stage of devel. at the beginning	Stage of devel. at the end							
	a	b	c	d			a	b	c	d									
1	1	0	0	0	F	H	1	0	0	0	F	H							
2	0	0	0	0	F	H	1	0	0	0	F	H							
3	1	0	0	0	F	H	1	0	0	0	F	H							
4	1	0	0	0	F	H	1	0	0	0	F	H							
5	1	0	0	0	G	H	1	0	0	0	G	H							
6	0	0	0	0	F	H	1	0	0	0	F	H							
7	1	0	0	0	F	H	1	0	0	0	F	H							
8	1	0	0	0	F	H	1	0	0	0	F	H							

a – presence of dentine bridge
 b – retardation of root growth
 c – presence of deformities
 d – presence of pathology in periapic region and pulp space
 1 – yes 0 – no

Table 2. Group 2. Pulpotomy at the level of enamel-cement junction

	Test teeth										Controls			
	Observed parameters				Stage of devel. at the beginning	Stage of devel. at the end	Observed parameters				Stage of devel. at the beginning	Stage of devel. at the end		
	a	b	c	d			a	b	c	d				
1	1	0	0	0	F	G	1	0	0	0	F	G		
2	1	0	0	0	F	G	1	0	0	0	F	G		
3	1	0	0	0	F	H	1	0	0	0	F	H		
4	1	0	0	0	F	H	1	0	0	0	F	H		
5	1	0	0	0	F	H	1	0	0	0	F	H		
6	0	0	0	0	F	H	1	0	0	0	F	H		
7	0	0	0	0	F	H	1	0	0	0	F	H		
8	1	1	0	0	F	H	1	0	0	0	F	H		

Table 3. Group 3. Pulpotomy at the point of radiographically visible point of immature root

		Test teeth				Controls							
		Observed parameters				Stage of devel. at the beginning	Stage of devel. at the end	Observed parameters				Stage of devel. at the beginning	Stage of devel. at the end
		a	b	c	d			a	b	c	d		
1	1	0	0	0	F	H	1	0	0	0	F	H	
2	1	0	0	0	F	H	1	0	0	0	F	H	
3	1	0	0	0	F	G	1	0	0	0	F	G	
4	1	1	1	0	F	G	1	0	0	0	F	G	
5	1	1	0	0	F	H	1	0	0	0	F	H	
6	0	0	1	0	F	G	1	0	0	0	F	G	
7	0	0	0	0	F	G	1	0	0	0	F	G	
8	1	0	0	0	F	G	1	0	0	0	F	G	

Root growth was evaluated radographically after direct pulp capping with synthetic hydroxiapatite *Behap*. Root formation was completed in all tested teeth at the same time as non-treated contralateral teeth and scored with "H" according to Demirijan's scale. Dentin bridge formation was observed in 6 out of 8 treated teeth. There were no significant differences in 4 observed parameters compared to controls.

Behap powder was applied on pulpal wound after the coronal part of the pulp was removed. Cavities were lined with glassionomer liners and filled with amalgam. As viewed on radiographs, root formation was completed in all tested teeth with the majority of both tested and control teeth being in the development stage "H" and physiological shapes. Dentin bridge formation was observed in 6 out of 8 tested teeth. There were no significant differences in 4 observed parameters compared to control teeth.

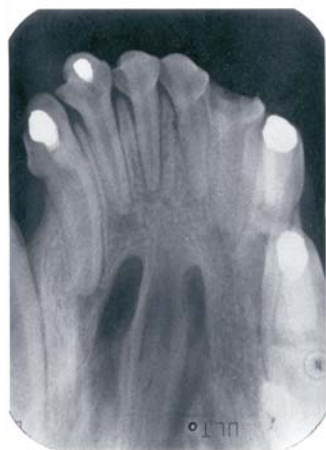

Figure 3. Direct pulp capping with Hap on second and third incisors. Apex growth is completed (stage G). Incomplete dentinal bridges are visible

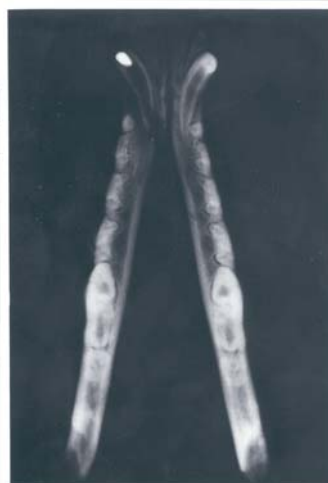

Figure 4. Lower left canine tooth 6 months after initial treatment: the root apex has matured to stage G; dentinal walls are thinner compared to the control tooth

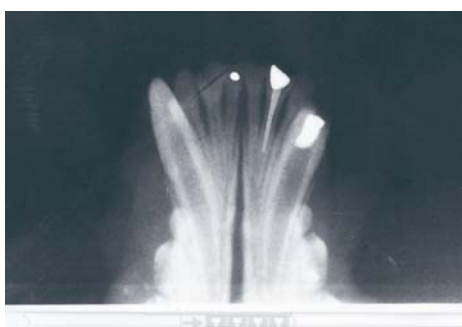

Figure 5. First central incisor after pulp capping: the apex has reached stage G. On the lateral incisor pulpotomy was performed at the point of radiographically visible point of immature root and filled with Silapex and gutapercha; the apex has matured to stage H. Pulpotomy at the e-c junction was performed on the canine; the apex growth has reached stage H

High amputations were performed and *Beohap* powder applied at the immature root end. The pulp space was filled permanently with gutapercha and Silapex, lined with glassionomer and filled with amalgam. The presence of dentine bridge tissue was observed in 6 cases. Root formation was completed in all tested teeth with deformities of root apex present in 4 teeth. Pathological changes in the periapical region and pulp space was not recorded in any of the cases.

DISCUSSION

By analyzing the radiographs, it was concluded that apexogenesis was successful in all tested teeth. There were no significant differences between the tested groups and controls (Fisher's and χ^2 test). Deformities of the root apex were present in two teeth (25%) in the third group. This can be explained by the possible damage caused during instrumentation, pulp extirpation and filling techniques. Dentine bridges or their parts are visible in almost all pulpotomized teeth. Radiographs did not reveal any pathology in the periapical tissue, obliteration of pulp space or the presence of denticles in the pulp.

Based on the results, it can be concluded that the use of a HAP material exhibited positive results in the treatment of teeth with incomplete root formation. The bioinductive potential of HAP led to successful pulp healing and dentine bridge formation, which is one of the conditions for successful apexogenesis. These results are promising and there might be an alternative to the routinely used calcium hydroxide in the treatment of teeth with immature apices, especially after recent studies showed decreased fracture resistance after filling with calcium hydroxide (Andreasen *et al.*, 2006). What we have noticed during the experiment, is that defining a suitable filler for easier manipulation would be helpful in clinical application. Other studies are also pointing out that right filler, the vehicles and the right combination of these agents with the tested material might be important (Mc Donald *et al.*, 2004). Comparing the influence of various biomaterials and combinations thereof (TCP+HAP, TCP+Mg, OCP-octocalcium phosphate) and Ca(OH)_2 on forming a dentine bridge in lab animals (porcine deciduous teeth), the best results were obtained with a mixture of TCP and HAP with a quicker formation of a superior quality dentine bridge than with other materials. (Jean *et al.*, 1998). Studying Osteogen® collagen and Ca(OH)_2 as possible apical sealants. Another group of researchers recommend using HAP in combination with collagen for this purpose due to the anticipated results, the stability of the combination of HAP and collagen and the ease of its application (Pissiotis and Spagberg, 1990). This combination also showed favourable results for augmenting the alveolar ridge, which gave rise to its possible application in endodontic treatment. (Martinez and Araujo, 2004).

The canine mandible model has been used extensively to investigate many aspects of healing following oral surgery, as well as to study the applications of various dental materials and lately, growth factors (Title *et al.*, 1996; Shabanhang and Torabinejad, 1999; Domingues *et al.*, 2003). Whilst this model has proved very useful, it has some shortcomings: the healing process is considerably shorter than in humans and care must be taken when extrapolating results from

this model to the human. There also appear to be wide variations in the response to wound healing of various breeds of dogs and their susceptibility to periodontal disease. The dogs used in this study were all cross-bred. All animals were in good health throughout the experiment. The radiographs taken at the beginning of the experiment showed all roots to be with wide open apices. When deciding about the clinical approach and vitality of the pulp in the developing tooth, radiographic interpretation can be difficult. A radiolucent area that normally surrounds the developing open apex of an immature tooth can be difficult to differentiate between this finding and pathologic radiolucency resulting from a necrotic pulp. Comparison with the periapex of the contralateral tooth maybe of help.

Hydroxyapatite is a standard material used in implantology (Cheong and Haak, 1988; Yamamuro an Hench, 1990; Yamamuro and Wilson, 1990). Research results concerning the reaction of dental pulp to HAP and HAP-induced dentine bridge formation following pulpotomies in monkeys have been contradictory at times. (Gregoire and Menentean, 1990). However, in the same animals, when HAP was used as a direct pulp-capping agent, it failed to produce complete dentinal bridges (Heys *et al.*, 1981). In order to study the osteogenic action of hydroxyapatite on dental pulp, direct pulp capping was performed in rats. After 28 days they observed globular dentine tissue of irregular distribution. However, Osteogen was not recommended for pulp capping purposes in humans because of areas of calcification that would make any future endodontic treatment difficult. (Jaber *et al.*, 1992). In our study, HAP material was introduced at 3 different levels of pulp exposure and the results are promising. Apexogenesis continued in much the same fashion as in the untreated control teeth; slight deformities were noted on radiographs only in the third group. Areas of calcification in the pulp space were not recorded.

Apexogenesis involves removal of the inflamed pulp and the placement of medicament, usually calcium hydroxide on the remaining healthy pulp tissue (AAPD Clinical Guidelines, 2004). Traditionally this has implied the removal of the coronal portion of the pulp. However, the depth to which the tissue is to be removed should be determined by clinical judgment. Only inflamed tissue should be removed, but the difficulty in assessing the level of inflammation is widely acknowledged (McDonald *et al.*, 2004). For that reason, the removal of the pulp tissue in this study was performed on three different levels including direct pulp capping, all with a succesful outcome. The Mann Whitney Test was used for statistical analysis in this study. Teeth with pre-treatment shapes which were convergent or parallel, all resulted in physiological shapes after treatment. Apical closure was obtained in 100% of the cases studied a further step would be to conduct histological studies and specific tissue responses after use of the tested material.

Address for correspondence:
Markovic Dejan:
Clinic of Preventive and Pediatric Dentistry,
School of Dentistry, University
11 000 Belgrade
Dr Subotića street 11, Serbia
E-mail: dejanmar@yubc.net

REFERENCES

1. Accorinte MLR, Reis A, Loguercio AD, Araujo VC, Muench A, 2006, Influence of rubber dam isolation on human pulp responses after capping with calcium hydroxide and adhesive system, *Quint Int*, 37, 3, 205-12.
2. Alliot-Licht B, Jean A, M.Gregoire M, 1994, Comparative effect of calcium hydroxide and hydroxyapatite on the cellular activity of human pulp fibroblasts in vitro, *Arch Oral Biol*, 39, 6, 481-9.
3. American Academy of Pediatric Dentistry, 2004, Clinical guideline on pulp therapy for primary and young permanent teeth, *Reference Manual*.
4. Andreasen JO, Munksgaard EC, Bakland LK. 2006, Comparison of fracture resistance in root canals of immature sheep teeth after filling with calcium hydroxide or MTA, *Dent Traum*, 22,154-6.
5. Cassidy N, Fahey M, Prime SS, Smith AJ, 1997, Comparative analysis of transforming growth factor- α isoforms 1-3 in human and rabbit dentine matrices, *Arch Oral Biol*, 42, 3, 219-3.
6. Cheong HS, Haak MH, 1988, Growth of osteoblasts on porous calcium phosphate ceramic, an in vitro model for biocompatibility study, *Biomater*, 10, 63-67.
7. Djordjevic M, 2004, Usporedno ispitivanje hidroksiapatita i kalcijum hidroksida kao materijala za direktno i indirektno prekrivanje pulpe, Doktorska disertacija, Beograd
8. Dominguez MS, Witherspoon, Gutmann JL, Opperman LA. 2003, Histological and scanning electron microscopy assessment of various vital-pulp therapy materials. *J Endod*, 29, 5.
9. Fellipe WT, Fellipe MCS, Rocha MJC, 2006, The effect of mineral trioxide aggregate on the apexification and periapical healing of teeth with uncomplete root formation, *Int End J*, 39, 2-9.
10. Gregoire M, Menanteau O, 1990, The influence of calcium phosphate biomaterials on human bone cell activities, an in vitro approach, *J Biomed Mat Res*, 24,163-77.
11. Heller AL, Koenings JF, Brilliant JD, Melfi RC, Driskell TD, 1975, Direct pulp capping of permanent teeth in primates using a resorbable form of tricalcium phosphate ceramic, *J Endod*, 3, 95-101.
12. Heys DR, Cox CF, Heys RJ, Avery JK, 1981, Histological considerations of direct pulp capping agents, *J Dent Res*, 60, 1371-9.
13. Jaber L, Mascres C, Donohue WB, 1992, Reaction of the dental pulp to hydroxyapatite, *Oral Surg Oral Med Oral Pathol*, 73, 92-8.
14. Jean A, Kerebel B, Kerebel LM, Lejeros RZ, Hamel H, 1998, Effects of Various calcium Phosphate Biomaterials on reparative Dentin Bridge Formation, *Jour of Endod*, 14, 2.
15. Markovic D, Zivojinovic V, Jokanovic V, Krstic N, 2006, Biocompatibility of nanostructured carbonated calcium hydroxyapatite obtained by hydrothermal method, *Acta Veterinaria*, 56 ,5-6, 541-53.
16. Martinez EF, Araujo VC, 2004, In vitro immunoexpression of extracellular matrix proteins in dental pulpal and gingival human fibroblasts. *Int Endod J*, 37, 749-55.
17. Mc Donald RE, Avery DR, Dean J, 2004. Treatment of deep caries, vital exposure and pulpless teeth. *Dentistry for the child and adolescent*, Mosby, Eight edition.
18. Mehlich DR, Taylor TD, Leibold DG, 1987, Evaluation of collagen/hydroxyapatite for augmenting deficient alveolar ridges, a preliminary report, *J Oral Maxillofac Surg*, 45, 408-13.
19. Olsson H, Davies JR, Holst KE, Schroder U, Petersson K, 2005, Dental pulp capping, effect of Emdogain Gel on Experimentally exposed human pulps, *Int Endod Jour*, 38,186-94.
20. Orly I, Gregoire M, Menanteau J, Dard M, 1989, Effects of synthetic calcium phosphates on the H-thymidine incorporation and alkaline phosphatase activity of human fibroblasts in culture, *J Biomed*, 23,1433-40.
21. Pissiotis E, Spangberg LSW, 1990, Biological Evaluation of Collagen Gels Conatining Calcium Hydroxide and Hydroxyapatite, *J Endod*,16,10.
22. Rafter M, 2005, Apexification, a review, *Dent Traumat*, 21, 1-8.
23. Schmitt D, Lee J, Bogen G, 2001, Multifaceted use of ProRoot MTA root canal repair material, *Pediatr Dent*, 23, 326-30.
24. Shabahang S, Torabinejad M. 1999, A comparative study of root-end induction using osteogenic protein-1, calcium hydroxide, and mineral trioxide aggregate in dogs, *J Endod*, 25, 1.

25. Shabahang S, Torabinejad M, 2000, Treatment of teeth with open apices using mineral trioxide aggregate. *Pract Periodont Aesthet Dent*, 12, 3, 315-20.
26. Salako N, Joseph B, Ritwik P, Salonen J, John P, Junaid TA, 2003, Comparison of bioactive glass, mineral trioxide aggregate, ferric sulfate, and formocresol as pulpotomy agents in rat molar, *Dent Traumat*, 19, 314 -20.
27. Silva AF, Tarquino FF, Demarco FF, Piva E, Rivero ERC, 2006, The influence of haemostatic agents on healing of healthy human dental pulp tissue capped with calcium hydroxide, *Int End J*, 39, 309-16.
28. Souza NJA, Justo GZ, Oliveira CR, HaunM, Bincoletto C, 2006, Cytotoxicity of materials used in perforation repair tested using the V79 fibroblast cell line and the granulocyte-macrophage progenitor cells, *Int End J*, 39, 40-7.
29. Subay RK, Asci S, 1993, Human pulpal response to hydroxyapatite and a calcium hydroxide material as direct capping agents, *Oral Surg Oral Med Oral Pathol*, 76, 4, 485-92.
30. Title K, Farley J, Linkhardt T, Torabinejad M, 1996, Apical closure induction using bone growth factors and mineral trioxide aggregate, *J Endod*, 22, 4.
31. Torneck CD, 1982, Effects and clinical significance of trauma to the developing permanent dentition, *Dent Clin North Am*, 26, 3.
32. Thesleff I, Vaahtokari A, 1992, The role of growth factors in determination and differentiation of the odontoblastic cell lineage, *Proc Finnish Dent Soc*, 20, 357-68.
33. Tziafas D, Alvanou A, Kaidoglou A, 1992, Dentinogenic activity of allogenic plasma fibronectin on dog dental pulp, *J Dent Res*, 71, 1189-95.
34. White JM, Goodis H, 1991, In vitro evaluation of an hydroxyapatite root canal system filling material, *J Endod*, 17, 1.
35. Yamamuro T, Hench LL, 1990, Handbook of bioactive ceramics, Bioactive glasses and glass-ceramics, Vol I CRC Press, Boca Raton, Florida.
36. Yamamuro T, Wilson J, 1990, Handbook of bioactive ceramics, Calcium phosphate and hydroxylapatite ceramics, Vol II CRC Press, Boca Raton, Florida.

RENDGENOLOŠKA PROCENA APEKSOGENEZE NAKON PRIMENE HIDROKSIAPATITA

MARKOVIĆ D, PETROVIĆ VANJA, KRSTIĆ N, LAZAREVIĆ-MACANOVIĆ MIRJANA
i NIKOLIĆ ZORANA

SADRŽAJ

Tretman pulpe u vreme kada jos uvek traje rast i razvoj korena predstavlja i dalje klinički izazov. Pored kalcijum hidroksida, najčešće i najduže upotrebljavanog medikamenta u ovakvim slučajevima, svakodnevno se testiraju i mnogi drugi materijali. Nakon što su se sintetski biomaterijali pokazali uspešnim u restauraciji kostnog tkiva uz njihovu priznatu biokompatibilnost i biokonduktivnost, naša namera je bila da istražimo mogućnost primene hidroksiapatita kao sintetskog biomaterijala u endodontskom tretmanu zuba sa nezavršenim rastom korena. U ovom istraživanju primenjen je Beohap, sintetski hidroksiapatit, prosečne veličine čestica $\approx 100 \mu\text{m}$, aplikovan na 24 zuba sa nezavršenim rastom korena kod tri psa uzrasta 5,5 meseci. Uzorci su kontrolisani radiografski i poređeni sa kontralateral-

nim netretiranim zubima do završetka rasta korena. Tretirani zubi su podeljeni u tri grupe: u prvoj je urađeno direktno prekrivanje pulpe, u drugoj je pulpa uklonjena do cementno-gleđne granice, a u trećoj je pulpa uklonjena do radiografski vidljivog vrha korena. Na osnovu analize rendgen filmova utvrđeno je da je formiranje vrha korena bilo završeno u sve tri grupe bez statističkih značajnosti razlika (Fisher's i χ^2 testovi) Deformiteti vrha korena uočeni su u 2 uzorka u trećoj grupi (25%).