

Case report

AN UNUSUAL CASE OF RAPIDLY FORMING SEVERE ORAL LESIONS INVOLVING BACTERIAL INFECTION IN A DOG

RAVNIK VERBIČ Urška^{1*}, PLAVEC Tanja¹, ZDOVC Irena², JUNTES Polona³, NEMEC Ana¹

¹Small Animal Clinic, Veterinary Faculty, University of Ljubljana, Ljubljana, Slovenia; ²Institute of Microbiology and Parasitology, Veterinary Faculty, University of Ljubljana, Ljubljana, Slovenia; ³Institute of Pathology, Wild Animals, Fish and Bees, Veterinary Faculty, University of Ljubljana, Ljubljana, Slovenia

(Received 21 September 2016 , Accepted 22 February 2017)

The term oronasal fistula refers to an acquired communication between the oral and nasal cavities, and can result from several conditions. However, oronasal fistula formation has not yet been described to be associated with bacterial infections. We have described in this case report for the first time a rapidly forming oronasal fistula and severe lingual lesions in a dog, involving an infection with *Streptococcus canis*. The patient was a 9-year-old male intact Golden Retriever with a nonspecific history of depression, mild pyrexia, anorexia and retching lasting for two days. Within four days he developed an extensive oronasal fistula, several pseudomembranous erosions, ulcerations and necrotic areas of the tongue and bronchopneumonia. Histopathology of the tongue revealed severe multifocal necrotizing and suppurative subchronic inflammation. *Streptococcus canis*, *Pasteurella multocida*, and *Staphylococcus pseudintermedius* were isolated from the bronchoalveolar lavage and the oronasal fistula. Despite the treatment, the dog developed necrotizing fasciitis and the owners elected euthanasia.

Key words: Dog; Group G streptococci; oronasal fistula; *Streptococcus canis*.

INTRODUCTION

Oronasal fistula is an acquired communication between the oral and nasal cavities caused in dogs by trauma (e.g., bite wounds, blunt head trauma, gunshot wounds, electrical burns, foreign body penetration and pressure necrosis, including nasopharyngeal stents) [1], neoplasia, radiation necrosis, dental disease and dehiscence after surgical treatment [2], the latest possibly complicated by nasal aspergillosis [3]. In humans, certain chemicals/drugs [4] and rhinoliths [5] have also been described to cause oronasal fistulae. Fungal and actinomycotic infections of the oropharynx may also result in subacute, invasive inflammatory processes with extensive tissue necrosis and oronasal fistulation in humans [6,7]. None of such possible causes for an oronasal

*Corresponding author: e-mail: urska.ravnik@vf.uni-lj.si

fistula formation has been identified in the case presented here. This report describes a case of an acquired oronasal fistula along with severe lingual lesions in a dog that had, to our knowledge, not been reported before.

CASE PRESENTATION

A 9-year-old male intact Golden Retriever was referred to the Small Animal Clinic of the Veterinary Faculty in Ljubljana for evaluation of depression, anorexia and retching lasting for 2 days. The owners reported no other significant history. Additional abnormalities reported by the referring veterinarian included mildly elevated body temperature (39.2°C), a subcutaneous mass (1.5×3 cm) in the left axillary region of a longer duration, chronic arthritis and digestion problems which were well controlled. The dog had been treated for 2 days with ranitidine (2.5 mg/kg/12 h *p.o.*) and amoxicillin (dose and route of administration unknown) with no improvement. On assessment, the dog was febrile (39.6°C) with bilaterally mildly enlarged mandibular lymph nodes. Clinical examination, including unsedated oral examination, was within normal limits. Results of a CBC, biochemistry panel, and urinalysis revealed mild nonregenerative anemia (RBC count $5.43 \times 10^{12}/L$, reference interval $5.7 - 8.8 \times 10^{12}/L$; hematocrit 0.36 L/L, reference interval 0.37 - 0.57 L/L) and proteinuria (1.0 g/L). Abdominal ultrasound was unremarkable, spinal radiographs revealed spondylosis between L7 - S1. The dog was treated symptomatically with maropitant citrate at 2 mg/kg/24 h *s.c.* (continued *p.o.*) and ranitidine at 2.5 mg/kg/12 h *s.c.* (continued *p.o.*) for a presumable gastric disease, and carprofen at 2 mg/kg/12 h *s.c.* (continued *p.o.*) and a single application of methadone at 0.33 mg/kg *s.c.* for analgesia due to presumable orthopedic pain (arthritis and spondylosis) resulting in pyrexia. A 4-day re-check revealed the dog to be afebrile, but still anorexic, with more pronounced retching. The dog also developed severe halitosis, dyspnea with a productive cough after exercise, purulent discharge from the right nostril and pseudomembranous erosions on the dorsum of the tongue and on the hard palate extending to the soft palate. Despite the questionable prognosis based on the clinical extent of the oral lesions, the client elected further diagnostics, where thoracic radiographs revealed a mildly enlarged right ventricle, increased radioopacity of the entire right cranial and middle lung lobes with bronchiectasis consistent with bronchopneumonia. Changes in the left cranial and caudal lung lobes were less severe. In addition, leucocytosis ($21.77 \times 10^9/L$, reference interval $5.2 - 13.9 \times 10^9/L$) with neutrophilia ($19.67 \times 10^9/L$, reference interval $3.9 - 8.0 \times 10^9/L$) and lymphopenia ($0.94 \times 10^9/L$, reference interval $1.3 - 4.1 \times 10^9/L$) were diagnosed. The dog was anaesthetized for rhinoscopy, bronchoalveolar lavage and detailed oral and oropharyngeal examination which revealed an extensive oronasal fistula and several pseudomembranous erosions, ulcerations and necrotic areas of the tongue (Fig. 1, 2). Bronchoalveolar lavage samples, as well as several biopsy samples, were obtained and submitted for microbiology (aerobic, anaerobic and fungal cultures with an antibiogram) and histopathology. Pending results, the dog was treated with

amoxicillin-clavulanate at 20 mg/kg/12 h *p.o.*, enrofloxacin at 5 mg/kg/24 h *p.o.*, carprofen at 2 mg/kg/12 h *p.o.*, and a fentanyl patch (100 µg/h). Hospitalization with an aggressive *i.v.* therapy was recommended to the owner due to rapidly developing severe clinical signs, but was declined. Histopathology of the tongue revealed severe multifocal necrotizing and suppurative subchronic inflammation extending from blood vessels into surrounding tissues. Lymphatic vessels were dilated and filled with fibrin. Many muscle cells in the tongue had undergone multifocal subacute and subchronic degenerative lesions including waxy hyaline degeneration, discoid fragmentation, atrophy of muscle cells, attempts of regeneration and connective tissue proliferation (Fig. 3). The epithelial layer was disrupted, ulcerated, covered with serofibrinous exudate and numerous colonies of Gram-positive cocci and rods. Lesions of the hard palate showed still active chronic inflammation with vascular proliferation, hyperplastic endothelial cells, tissue infiltration with many vacuolated macrophages and plasma cells. Multifocal acute hemorrhages and clusters of neutrophils were present in small necrotic areas with a protein rich exudate forming around small blood vessels filled with densely packed erythrocytes. These lesions were consistent with severe circulatory disturbances of the terminal blood vessels. A thick layer of tissue debris and fibrinopurulent exudate with numerous Gram-positive colonies was present on the hard palate surface, similar to the tongue. All lesions were histologically negative for fungi and yeasts with Periodic Acid Schiff (PAS) staining and negative for acid fast organisms with Ziehl-Neelson staining. *Streptococcus canis* (*S. canis*), *Pasteurella multocida* (*P. multocida*) and *Staphylococcus pseudintermedius* (*S. pseudintermedius*) were isolated from the bronchoalveolar lavage as well as from the samples obtained from the oronasal fistula, where alfa-hemolytic streptococci were also found. There were no fungi and yeasts cultured. An antibiogram confirmed the sensitivity of the isolated bacteria to most commonly used antibiotics (including amoxicillin-clavulanate and enrofloxacin), but the dog's condition did not improve on the *p.o.* therapy. An aggressive *i.v.* antibiotic therapy was started 2 days after sampling (8 days after the initial presentation) (amoxicillin-clavulanate at 20 mg/kg/12 h, metronidazole at 15 mg/kg/12 h, gentamicin at 5 mg/kg/24 h), with supportive fluid and analgesic therapy. Despite the treatment, the dog developed bilateral skin lesions on the thorax (below the harness), which clinically resembled necrotizing fasciitis. Due to deteriorating condition and poor prognosis the owners elected euthanasia and declined autopsy.

Abundant numbers of group G streptococci were cultured from the oronasal fistula and lungs of the affected dog. Group G streptococci are commensal organisms in dogs residing in the skin and mucous membranes. They are opportunistically pathogenic and are often isolated from non-specific urogenital, upper respiratory, mammary gland, and skin infections [8, 9]. Group G streptococci, most frequently *S. canis*, can cause septicemia and polyarthritis in puppies, and pneumonia, endocarditis, keratitis, cholangiohepatitis, arthritis, meningoencephalitis, and myositis in adults [10, 11]. *S. canis* is also a major etiological agent of soft tissue infections - necrotizing fasciitis (NF), and streptococcal toxic shock syndrome in dogs [11-13].

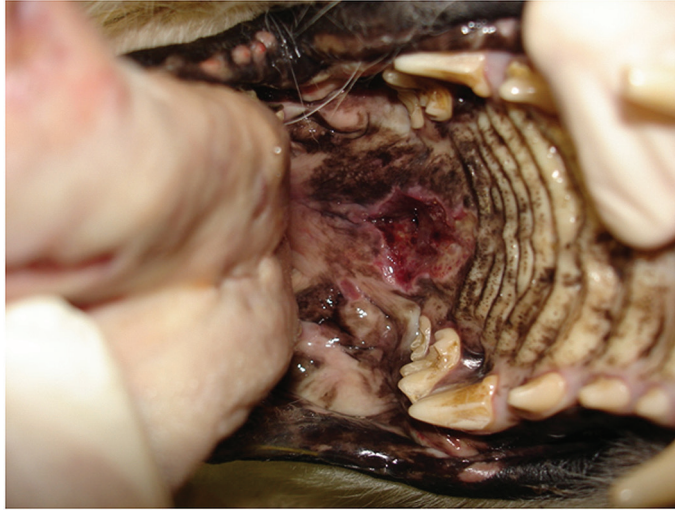

Figure 1. Oronasal fistula

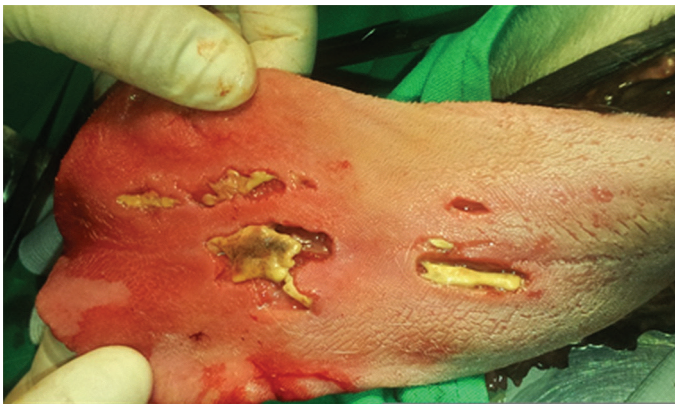

Figure 2. Pseudomembranous erosions, ulcerations and necrotic areas of the tongue

To cause NF and later streptococcal toxic shock syndrome, bacteria presumably have to invade fascial tissues through (minor) wounds/trauma such as bite wounds, surgical trauma and skin infections [11] although NF was reported also after dental treatment [14]. Affected animals develop fever, lethargy, rapidly progressing cellulitis associated with an intense pain localized around the affected area [9]. In the case presented here, in addition to *S. canis*, *P. multocida* and *S. pseudintermedius* were also isolated from both the oronasal fistula and the lungs. Both bacteria are also commensals in dogs, may cause severe soft tissue monoinfections including NF, but reports on this are rare [15, 16]. The exact role of the three bacterial species isolated from our patient is not clear, but their synergistic activity is possible, resulting in a rapidly progressing disease. Further, streptococci are generally sensitive to penicillin, but when large numbers of slow-growing bacteria are present, antibiotic may be less effective because of the

decreased expression of penicillin-binding proteins [17, 18]. These are presumably the reasons for the rapid progression of the disease in our patient despite the antibiotic treatment.

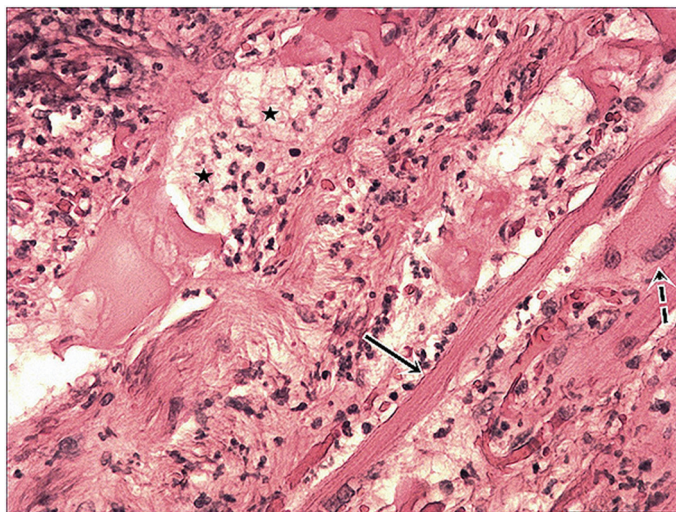


Figure 3. Tongue. Necrotic tissue on the left top corner and inflamed lingual muscles in different stages of degeneration and attempts of regeneration. Discoidal degeneration with phagocytes clearing the area (stars), atrophic muscle cell (full arrow) and abortive regeneration (interrupted arrow). HE, x 200.

The exact route of infection and sequel of events in the case presented here also remain unclear. Namely, the dog presented here had very nonspecific initial signs of anorexia and retching, which are common signs of gastric disease as initially presumed in this patient with a history of digestion problems. However, in retrospect, those were likely signs of oropharyngeal irritation and/or pain that may have been elicited by a minor, unnoticed trauma to the oropharynx. A minor injury to the oral soft tissues would then act as a door for severe infection of the oral soft tissues (similar to NF) with an oronasal fistula development and subsequent aspiration pneumonia. On the other hand, fever, nonregenerative anemia, and proteinuria could be attributed to various non-specific infections, but might had been early signs of pneumonia with expectorated bacteria then infecting a possible minor wound in the oral cavity.

Similar cases of rapidly progressing *S. canis* infection of the maxillofacial region were reported in cats before. Taillefer and Dunn [19] reported on a toxic shock-like syndrome in three cats that started with oral ulcers and pyrexia and developed into bacterial pneumonia and/or pleuritis. In addition, Pesavento et al. [20] described two fatal outbreaks with suppurative, necrotizing sinusitis and rhinitis with necrosis and perforation of the nasal bone and progression into surrounding tissues. However, to the authors' knowledge, this is the first case demonstrating that severe oral lesions including an oronasal fistula may rapidly develop as a sequel of bacterial infection also in a dog.

Authors' contributions

RVU made primary clinician on a case and drafted the manuscript. PT and NA consulting clinicians on a case, proposed the idea to write a case report and revised the manuscript. ZI performed microbiological determination and revised the manuscript. JP performed histopathological determination and revised the manuscript.

Declaration of conflicting interests

The author(s) declared no potential conflicts of interest with respect to the research, authorship, and/or publication of this article.

REFERENCES

1. Cook AK, Mankin KT, Saunders AB, Waugh CE, Cuddy LC, Ellison GW: Palatal erosion and oronasal fistulation following covered nasopharyngeal stent placement in two dogs. *Ir Vet J* 2013,66: 8.
2. Manfra Marretta S: Repair of acquired palatal defects. In: *Oral and maxillofacial surgery in dogs and cat*, Eds Verstraete FJM, Lommer MJ. Edinburgh, UK: Saunders Elsevier; 2012, 363-372.
3. Peralta S, Nemeč A, Fiani N, Verstraete FJ: Staged double-layer closure of palatal defects in 6 dogs. *Vet Surg* 2015, 44: 423-431.
4. Sloan PA, Klimkina O: Intranasal abuse of prescription hydrocodone/acetaminophen results in oronasal fistula: a case report. *J Opioid Manag* 2009, 5: 383-385.
5. Igoumenakis D, Athanasiou S, Mezitis M: A bizarre cause of extensive oronasal fistula. *J Craniofac Surg* 2013, 24: 483-484.
6. Fonseca VA, Reis G, Alves C, Simoes MJ, Camacho E, Saraiva AP: A rare case of co-infection with pulmonary tuberculosis and oronasal actinomycosis. *J Bras Pneumol* 2009, 35: 1152-1155.
7. Manfredi R, Mazzoni A, Cavicchi O, Santini D, Chiodo F: Invasive mycotic and actinomycotic oropharyngeal and craniofacial infection in two patients with AIDS. *Mycoses* 1994, 37: 209-215.
8. Biberstein EL, Hirsh DC (1999) Streptococci. In: *Veterinary Microbiology*, Eds Hirsh DC, Zee YC. Malden, MA: Blackwell Science; 1999, 120-126.
9. Naidoo SL, Campbell DL, Miller LM, Nicastro A: Necrotizing fasciitis: A Review. *J Am Anim Hosp Assoc* 2005, 41: 104-109.
10. Lamm CG, Ferguson AC, Lehenbauer TW, Love BC: Streptococcal Infection in Dogs: A Retrospective Study of 393 Cases. *Vet Pathol* 2010, 47: 387-395.
11. Prescott JF, DeWinter L: Canine streptococcal toxic shock syndrome and necrotising fasciitis. *Vet Rec* 1997, 140: 263.
12. Miller CW, Prescott JF, Mathews KA, Betschel SD, Yager JA, Guru V, DeWinter L, Low DE: Streptococcal toxic shock syndrome in dogs. *J Am Vet Med Assoc* 1996, 209: 1421-1426.
13. Prescott JF, Miller CW, Matthews KA, Yager JA, DeWinter L: Update on canine streptococcal toxic shock syndrome and necrotizing fasciitis. *Can Vet J* 1997, 38: 241-242.

14. Plavec T, Zdovc I, Juntos P, Svava T, Suhadolc Scholten S, Nemec A, Domanjko Petric A, Tozon N: Necrotizing fasciitis caused by *Serratia marcescens* after tooth extraction in a Doberman Pinscher: a case report. Veterinarni Medicina 2008, 53: 629-635.
15. Weese JS, Poma R, James F, Buenviaje G, Foster R, Slavic D: *Staphylococcus pseudintermedius* necrotizing fasciitis in a dog. Can Vet J 2009, 6: 655-656.
16. Banovic F, Linder K, Boone A, Jennings S and Marcia Murphy K: Cat scratch-induced *Pasteurella multocida* necrotizing cellulitis in a dog. Vet Dermatol 2013, 24: 463-465.
17. Cunningham JD, Silver L, Rudikoff D: Necrotizing fasciitis: a plea for early diagnosis and treatment. Mt Sinai J Med 2001, 68: 253-261.
18. Leitch JA, Palepu A, Fernandes C: Necrotizing fasciitis secondary to group A streptococcus. Morbidity and mortality still high. Can Fam Physician 2000, 46: 1460-1466.
19. Taillefer M, Dunn M: Group G Streptococcal toxic shock-like syndrome in three cats. J Am Anim Hosp Assoc 2004, 40: 418-422.
20. Pesavento PA, Bannasch MJ, Bachmann R, Byrne BA, Hurley KF: Fatal *Streptococcus canis* infections in intensively housed shelter cats. Vet Pathol 2007, 44: 218-221.

SLUČAJ NEOBIČANO BRZOG FORMIRANJA IZRAŽENIH ORALNIH LEZIJA UDRUŽENIH SA BAKTERIJSKOM INFEKCIJOM KOD PSA

RAVNIK VERBIČ Urška, PLAVEC Tanja, ZDOVC Irena, JUNTES Polona, NEMEC Ana

Pojam oronazalna fistula se odnosi na novoformiranu komunikaciju između usne i nosnih šupljina, a nastaje kao posledica nekoliko patoloških stanja. Međutim, formiranje oronazalne fistule do sada nije bio opisan kao posledica bakterijske infekcije. Po prvi put je opisan slučaj brzog formiranja oronazalne fistule i izraženih lezija jezika psa, uključujući infekciju sa *Str. canis*. Pacijent, je bio star 9 godina, rase zlatni retriever sa anamnezom: depresija, blaga pireksija, anoreksija i nagon za povraćanjem. Simptomi su trajali dva dana. U vremenskom periodu od 4 dana, razvila se izražena oronazalna fistula, nekoliko pseudomembranoznih promena i erozija, ulceracije i nekrotične oblasti na jeziku kao i bronhopneumonija. Histopatološka ispitivanja tkiva jezika su pokazala teško nekrotizujuće i supurativno subhronično zapaljenje. Iz bronhoalveolarne lavaže i oronazalne fistule, izolovane su bakterije *Streptococcus canis*, *Pasteurella multocida* i *Staphylococcus pseudintermedius*. Uprkos tretmanu i terapiji, kod psa se razvio nekrotizujući fasciitis pa se vlasnik odlučio da se nad psom obavi eutanazija.