

ACCURACY AND RELIABILITY OF MEASUREMENTS OBTAINED FROM 3-DIMENSIONAL RABBIT MANDIBLE MODEL: A MICRO-COMPUTED TOMOGRAPHY STUDY

REMZI Orkun Akgün^{1,*}, CANER Bakıcı¹, OKAN Ekim¹, UFUUK Kaya²,
NURIYE Özlem Küçük^{3,4}

¹Ankara University, Faculty of Veterinary Medicine, Department of Anatomy, Ankara, Turkey;

²Ankara University, Faculty of Veterinary Medicine, Department of Biostatistics, Ankara, Turkey;

³Ankara University, School of Medicine, Department of Nuclear Medicine, Ankara, Turkey;

⁴Ankara University, Cancer Research Institute, Ankara, Turkey

(Received 18 March, Accepted 23 May 2019)

The aim of this study was to evaluate the mandibular morphometric measurements of male and female rabbits using three-dimensional digital model and real bone measurements. Ten (5 female, 5 male) rabbits with no bone deformities were used in the study. Three-dimensional models were produced from two-dimensional micro-computed tomography images of the rabbit's mandible. Biometric data were obtained by using the same measuring points over both three-dimensional models and real bone samples. There was only a significant main effect of gender for the greatest length of the mandible, length from aboral border of the alveolus of third molar teeth to infradentale, length of the diastema, height of the vertical ramus (measured in projection), distance from the incisor to the oral border of mental foramen, distance from aboral border of mental foramen to caudal border of mandible, distance between retroalveolar foramen and caudal border of mandible. For these measurements, calculated data for females are significantly higher than the males ($p < 0.05$). It was found to be statistically significant between methods only for the length of the cheek tooth row and height of the vertical ramus values ($p < 0.05$). In this study, it was understood that 3D morphometric measurements for bone tissue could be used with accuracy and reliability especially in anatomy and orthodontics areas as an alternative to traditional measurements made with a digital caliper.

Key words: Mandible, Micro computed tomography, Morphometry, Rabbit, Three-dimensional reconstruction.

INTRODUCTION

Experimental studies on laboratory animals are very important to improve the diagnosis and treatments for human medicine. Various animal models are frequently used in experimental researches. Laboratory rabbit is mostly preferred in orthopedic studies for muscle and skeletal structures [1,2]. Moreover, the laboratory rabbit is one

*Corresponding author: e-mail: akgunorkun@hotmail.com

of the most widely used models in bone remodeling and dental implants [3]. There are many morphological studies using the rabbit mandible. Akbulut *et al.* [4], Monfared [5], and Salih [6] examined the morphometric data taken by a digital caliper from the mandible of male and female rabbits. Akbulut *et al.* [4] stated that sex differentiation could not be performed due to minimal measurement differences while Salih [6] emphasized that the female measurements were bigger than the ones taken on males. The obtained results could be useful for anesthesia applications in the case of head injuries [5]. El-Bialy *et al.* [7] investigated the effect of therapeutic ultrasound (US) on mandibular morphometry. It was reported that the use of low intensity ultrasound increased the height of the mandible in growing rabbits. Borie *et al.* [8] evaluated the measurements of anatomical regions used in oral surgery and implant applications in rabbits. It was indicated that the limited sizes of anatomical structures should be considered when working with important size deformities in rabbits in order to avoid complications. Valdivia *et al.* [9] investigated the effect of neural stimulation on mandibular morphometry. It was reported that there was no significant difference in the maximum anterior-posterior length between denervated and non-denervated hemimandibles.

However, it was seen that the 3D radiological studies related the healthy mandible morphology and morphometry of the laboratory rabbits were quite limited.

Depending on the technology, medical imaging methods that are constantly developing provide many benefits to medicine. Micro computed tomography (μ CT), a modern imaging technique, provides detailed information on bone morphology in experimental animal models. It is used effectively for the determination of very small anatomical structures of bone tissue [10]. 3D anatomical models can be produced by using various software programs from 2D cross-sectional images obtained by the μ CT method. 3D models provide a better understanding of complex anatomical structures. The location of an anatomical structure having a complex topography can be easily defined on 3D models [11]. 3D models or digital images are used effectively for preoperative surgical planning and simulations [12]. In addition, biometric measurements of the desired region can be made easily on the anatomical structure using models. The accuracy and reliability of linear and angular measurements over 3D models have been clearly stated in recent studies [12-14].

In this study, it was aimed to produce 3D models of the mandible of female and male rabbits by using the μ CT technique, and to evaluate the morphometric data measured on models statistically. At the same time, it was aimed to determine the accuracy and reliability of the 3D measurements by comparing them with the measured values taken from the same points using the digital caliper.

MATERIAL AND METHOD

Ten (5 female, 5 male) adult (1 year old / 2500-3000 g) New Zealand rabbits with no bone deformation were used in the study. This study was approved by Ankara

University Animal Experiments Local Ethics Committee (Decision no: 2019-3-19). Firstly, rabbit mandibles were dissected and imaged with the μ CT device (Super Argus PET / CT, Sedecal, Spain). Image processing was performed at standard resolution, 0.12 mm slice thickness, 40 kV and 140 mA. 2D images were uploaded to the 3D Slicer software program (3D slicer, 4.11.0 version, GitHub, San Francisco) in DICOM file format. During the segmentation phase, the ‘threshold’ command was used to separate the bone tissue from other tissues. After the bone tissue was segmented, 3D models were created. Anatomical structures were defined on 3D models and morphometric measurements were performed. After the 3D measurement process, the same measurements were performed using digital caliper (Mitutoyo Corporation, CD-15D, Japan) over organic bone samples. Each measurement was made two times by the same two examiners and the average value was considered. The measurement points were determined according to the related literature [4-6,15]. The measurements were indicated on the 3D mandible models (Fig. 1). The data were evaluated statistically by taking into account both the gender factor and measurement methods. Before performing the statistical analysis, data were examined with the Shapiro - Wilk test for normality and Levene test for homogeneity of variances as parametric test assumptions. Descriptive statistics for each variable were calculated and presented as “Mean \pm Standard Error of Mean”. Data were analyzed using the General Linear Model for Repeated Measures procedure. The model included “gender” and “method” as the main effects and “gender*method” interaction effects. A probability value of less than 0.05 was considered significant, unless otherwise noted. SPSS 14.01 was used for statistical analysis.

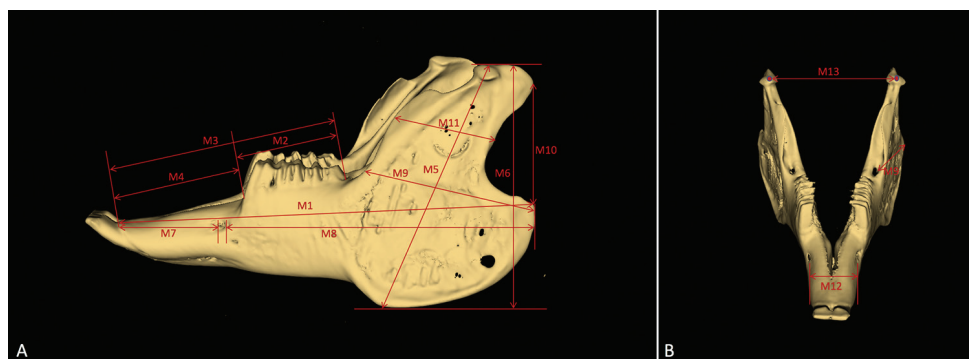


Figure 1. Measurement points identified on 3D models (A: Left side; B: Craniodorsal side). M1- Greatest length of mandible: gonion caudale – infradentale; M2- Length of the cheek tooth row; M3- Aboral border of the alveolus of M_3 – infradentale; M4- Length of the diastema; M5- Height of the vertical ramus: gonion ventrale – highest point of the condylar process; M6- Height of the vertical ramus, measured in projection; M7- Distance from incisor to oral border of mental foramen; M8- Distance from aboral border of mental foramen to caudal border of mandible; M9- Distance between retroalveolar foramen and caudal border of mandible; M10- Distance between condylar process and angular process; M11- The breadth of the mandibular ramus; M12- Breadth of the mandibular body; M13- Distance between left and right condylar process: measured from middle point.

RESULTS

Three-dimensional mandible models of female and male rabbits were produced successfully in this study (Fig. 1). The measurement results of both 3D models and organic bone samples were given in Table 1. The gender*method interaction term was found statistically significant for M2 and M5 values ($p < 0.05$). There was no statistically significant difference between both genders and methods for M10, M11, M12 and M13 ($p > 0.05$) (Table 1). There was only significant main effect of gender for M1, M3, M4, M6, M7, M8 and M9 values indicating that calculated values of females are significantly higher than the males ($p < 0.05$) (Table 1).

Table 1. Mandible measurement values collected from 3D models and organic bone samples (Mean \pm Standard Error of Mean)

Measurement	Gender	Method		P		
		3D model	Digital caliper (Organic bone)	Gender	Method	Gender* Method
M1	F	66.960 \pm 0.224	67.304 \pm 0.262	<0.001	0.731	0.081
	M	62.260 \pm 0.224	62.020 \pm 0.262			
M2	F	16.260 \pm 0.266 ^a	15.214 \pm 0.141 ^{b, B}	0.942	0.032	0.025
	M	15.740 \pm 0.266	15.768 \pm 0.141 ^A			
M3	F	38.160 \pm 0.127	38.278 \pm 0.124	<0.001	0.586	0.100
	M	35.060 \pm 0.127	34.838 \pm 0.124			
M4	F	21.960 \pm 0.232	22.232 \pm 0.276	<0.001	0.085	0.061
	M	19.780 \pm 0.232	19.766 \pm 0.276			
M5	F	42.760 \pm 0.289 ^{b, A}	43.886 \pm 0.454 ^{a, A}	<0.001	0.236	0.035
	M	40.000 \pm 0.289 ^B	39.630 \pm 0.454 ^B			
M6	F	41.180 \pm 0.245	41.666 \pm 0.381	<0.001	0.871	0.167
	M	37.020 \pm 0.245	36.414 \pm 0.381			
M7	F	15.960 \pm 0.303	15.800 \pm 0.265	0.001	0.192	0.852
	M	13.780 \pm 0.303	13.658 \pm 0.265			
M8	F	47.280 \pm 0.216	46.744 \pm 0.184	0.001	0.532	0.141
	M	46.100 \pm 0.216	46.330 \pm 0.184			
M9	F	27.520 \pm 0.222	27.002 \pm 0.275	0.002	0.294	0.223
	M	26.000 \pm 0.222	26.042 \pm 0.275			
M10	F	16.740 \pm 0.226	16.506 \pm 0.389	0.663	0.723	0.553
	M	16.420 \pm 0.226	16.480 \pm 0.389			
M11	F	15.180 \pm 0.207	14.550 \pm 0.423	0.942	0.079	0.482
	M	14.980 \pm 0.207	14.688 \pm 0.423			
M12	F	10.894 \pm 0.408	10.592 \pm 0.304	0.790	0.192	0.598
	M	10.980 \pm 0.408	10.300 \pm 0.304			
M13	F	28.260 \pm 0.662	28.230 \pm 0.501	0.083	0.775	0.862
	M	26.740 \pm 0.662	26.618 \pm 0.501			

^{a, b}: Different letters on the same line indicate statistically significant difference ($p < 0.05$)

^{A, B}: Different letters on the same column indicate a statistically significant difference ($P < 0.05$)

DISCUSSION

In the literature research, it was seen that measurement processes of the rabbit mandible were performed by using a digital caliper on organic bone samples. Akbulut et al. [4] have analyzed the effect of gender factor on the mandible morphometry in the New Zealand Rabbit. It was stated that the values of males were higher than that of females in all measurements, but not statistically significant. The greatest length of mandible was indicated to be 66.62 mm and 66.15 mm in males and females, respectively. In our study, the values obtained by both methods in females were found to be quite similar to that reported in the literature, while the values of males were found to be lower than that indicated in the literature. In males, the average measurement data were found 62.26 mm and 62.02 mm for 3D and digital caliper measurements, respectively. The average measurements for height of the vertical ramus were reported 44.86 mm in males and 44.82 mm in females. In our study, the average values calculated with 3D and digital caliper measurements for males and females were lower than those reported in the literature. For females, the average data were found 41.18 mm and 41.66 mm for 3D and digital caliper measurements, respectively. In males, these values were 37.02 mm for 3D method and 36.41 mm for digital caliper method. In the literature, the average values of length of the cheek tooth row were calculated 16.28 mm and 16.55 mm in females and males, respectively. For this measurement region, mean digital caliper measurements were slightly lower in both genders (for males 15.77 mm, for females 15.21 mm) than in the literature. The average value of females was 16.26 mm in the 3D measurement results and it was found to be very close to the value specified in the literature. The morphometric average values for the distance from the aboral border of mental foramen to the caudal border of the mandible were indicated 48.01 mm in females, 48.76 mm in males. The mean values of 3D and digital caliper measurements in both genders were found to be close to the values in the literature but slightly lower. While 3D average measurements were 47.28 mm and 46.10 mm for females and males, digital caliper measurements were 46.74 mm and 46.33 mm for females and males, respectively. The distance values of the alveolus of third molar teeth (M_3) - infradentale were reported 38.01 mm for females and 38.24 mm for males. In our study, 3D and digital caliper values of females were found to be very close to those in the literature, whereas values in males were found to be lower. For females, the average data were calculated 38.16 mm and 38.27 mm for 3D and digital caliper measurements, respectively. In males, these values were 35.06 mm for 3D method and 34.83 mm for digital caliper method. In the literature, the morphometric values for length of diastema were indicated 21.51 mm in females and 21.97 mm in males. In our study, the values of females and males were determined as 21.96 mm and 19.78 mm for 3D measurements, while the values of females and males were determined as 22.23 mm and 19.77 mm for digital caliper measurements, respectively. For this measurement region, compared with the results in the published literature, the mean values in 3D and digital caliper measurements of females was slightly higher, while those of the males was slightly lower in this study.

Salih [6] has investigated the morphology and morphometry of the mandible in New Zealand Rabbit. In the females and males, the morphometric values of the breadth of the mandibular body were reported to be 10.68 mm and 9.55 mm, respectively. In this study, the values we obtained from this region were consistent with the literature. The average values obtained from both methods in males were slightly higher than in the literature. The values of females and males were determined as 10.89 mm and 10.98 mm for 3D measurements, while the values of females and males were calculated as 10.59 mm and 10.30 mm for digital caliper measurements, respectively. The measurement values of the distance between the left and right condylar process were reported 29.68 mm and 26.95 mm in females and males, respectively. In this study, the values of females obtained with each method were slightly lower than the values given in the literature. The average data of females were determined 28.26 mm and 28.23 mm using 3D and digital caliper measurements, respectively. The average measurement data for distance from incisor to oral border of the mental foramen were indicated 12.02 mm in females and 12.01 mm in males. In our study, the values obtained for the measurement were found to be higher in both females and males than that indicated in the literature. For females, the average data were determined 15.96 mm and 15.80 mm for 3D and digital caliper measurements, respectively. In males, these values were 13.78 mm for 3D method and 13.65 mm for digital caliper method.

El-Bialy *et al.* [7] have investigated the effect of therapeutic ultrasound on the development of the mandible in male rabbits. The height of the vertical ramus measured 32.4 mm in animals treated with ultrasound, while it was 29.5 mm in untreated animals. In this study, the average values obtained by 3D and digital caliper measurements in males were 37.02 mm and 36.41 mm, respectively.

Borie *et al.* [8] have performed a morphometric research on rabbit mandible for experimental implantation and oral surgery. The average measurement value of the greatest length of the mandible has been reported as 67.20 mm. In the study, the average value of digital caliper of females was 67.30 mm, while the value of males was 62.02 mm.

Monfared [5] has indicated the measurement values of the height of the vertical ramus, distance from incisor to oral border of mental foramen and distance from the aboral border of mental foramen to the caudal border of the mandible 29.3 mm, 18.90 mm and 53.00 mm, respectively. In this study, the measurement value of the height of the vertical ramus in rabbits was higher than that reported in the literature, while the values of distance from incisor to oral border of mental foramen and distance from the aboral border of mental foramen to the caudal border of the mandible were lower than that indicated in the literature (Table 1).

Kim *et al.* [12] have compared 3D skull measurements obtained multidetector computed tomography (MDCT) and cone beam computer tomography (CBCT) images with digital caliper measurements performed on dry skulls. It has been reported that 3D measurements can be used safely in morphometric studies. Stull *et al.* [13] have stated

that the accuracy of the measurements taken by using 3D models were very high. In this study, measurements on 3D models obtained from μ CT images were in parallel with digital caliper measurements.

Azer and Azer [16], Murgitroyd et al. [17] and Özkadif and Eken [18] have stated that 3D models in medicine, dentistry and other health fields can be used to improve students learning skills. It is thought that the models obtained in our study can be used safely as educational material in anatomy and orthopedy.

Murgitroyd et al. [17], in their study, have stated that 3D models were very beneficial to the surgeons in the pre-operative planning. They also indicated that 3D modeling increases the confidence of surgeons during the operation time. It is foreseen that 3D mandible model and measurements obtained in this study will be a resource for scientists in experimental mandible surgery in rabbits.

In conclusion, it was seen that 3D measurement values were quite similar with digital caliper measurement values. Therefore, 3D morphometric measurements for bone tissue can be used with accuracy and reliability especially in anatomy and orthodontia as an alternative to traditional measurements made on organic samples.

Authors' contributions

ROA, CB and OE actively participated in the design of the study and performed the anatomical analysis. UK carried out the statistical analysis. NÖK performed imaging stage and set the μ CT parameters. The manuscript was written by ROA and CB. OE contributed to language editing of the final manuscript. All authors read and approved the final manuscript.

Declaration of conflicting interests

The author(s) declared no potential conflicts of interest with respect to the research, authorship, and/or publication of this article.

REFERENCES

1. Martini L, Fini M, Giavaresi G, Giardino R: Sheep model in orthopedic research: A literature review. *Comparative Med* 2001, 51(4): 292-299.
2. Neyt JGV, Buckwalter JA, Carroll NC: Use of animal models in musculoskeletal research. *Iowa Orthop J* 1998, 18: 119-123.
3. Campillo VE, Langonnet S, Pierrefeu A, Chauv-Bodard AG: Anatomic and histological study of the rabbit mandible as an experimental model for wound healing and surgical therapies. *Lab Anim* 2014, 48(4): 273-277.
4. Akbulut Y, Demiraslan Y, Gürbüz İ, Aslan K: The effect of gender factor on the mandible morphometry in the New Zealand Rabbit. *FÜ Sağ Bil Vet Derg* 2014, 28(1): 15-18.

5. Monfared AL: Applied anatomy of the rabbit's skull and its clinical application during regional anesthesia. *Glob Vet* 2013, 10(6): 653-657.
6. Salih QM: Morphological and morphometric study of the mandible in the local rabbits (*Oryctolagus Cuniculus*). *Iraqi J Vet Sci* 2016, 40(1): 25-29.
7. El-Bialy T, El-Shamy I, Graber TM: Growth modification of the rabbit mandible using therapeutic ultrasound: Is it possible to enhance functional appliance results? *Angle Orthod* 2003, 73(6): 631-639.
8. Borie E, Calzzani R, Dias FJ, Fuentes R, Salamanca C: Morphometry of Rabbit anatomical regions used as experimental models in implantology and oral surgery. *Biomed Res* 2017, 28(12): 5468-5472.
9. Valdivia GI, Tallon WV, Carvalho LP, Lozano LV, Manzanares CMC: Mandible measurements and dental midline deviation after alveolar nerve transection in growing rabbits. *Int J Morphol* 2011, 29(1): 52-56.
10. Jiang Y, Zhao J, White DL, Genant HK: Micro CT and Micro MR imaging of 3D architecture of animal skeleton. *J Musculoskel Neuron Interact* 2000, 1: 45-51.
11. Estai M, Bunt S: Best teaching practices in anatomy education: A critical review. *Ann Anat* 2016, 208: 151-157.
12. Kim M, Huh KH, Yi WJ, Heo MS, Lee SS, Choi SC: Evaluation of accuracy of 3D reconstruction images using multi-detector CT and cone-beam CT. *Imaging Sci Dent* 2012, 42: 25-33.
13. Stull KE, Tise ML, Ali Z, Fowler DR: Accuracy and reliability of measurements obtained from computed tomography 3D volume rendered images. *Forensic Sci Int* 2014, 238: 133-140.
14. Vicilli R, Katona T, Roberts W: Optimization of μ CT data processing for modelling of dental structures in orthodontic studies. *Comput Methods Biomech Biomed Engin* 2007, 10(4): 257-263.
15. Driesch AVD: A Guide to the measurement of animal bones from archaeological sites. *Pea body Museum Bulletin* 1. Harvard University, Massachusetts, 1976, 52-64.
16. Azer SA, Azer S: 3D anatomy models and impact on learning: A review of the quality of the literature. *Health Professions Education* 2016, 2: 80-98.
17. Murgitroyd E, Madurska M, Gozalez J, Watson A: 3D digital anatomy modelling -Practical or pretty? *Surgeon* 2015, 13: 177-180.
18. Özkadif S, Eken E: Contribution of virtual anatomic models to medical education. *Atatürk Üniversitesi Vet Bil Derg* 2015, 10(1): 46-54.

TAČNOST I POUZDANOST MERA DOBIJENIH U TRODIMENZIONALNOM MODELU MANDIBULE KUNIĆA: MODEL STUDIJE MIKRO-KOMPJUTERIZOVANE TOMOGRAFIJE

REMZI Orkun Akgün, CANER Bakıcı, OKAN Ekim, UFUK Kaya, NURIYE Özlem Küçük

Cilj studije je bio da se procene morfometrijske mere mandibule kunića ženskog i muškog pola, upotrebom trodimenzionalnog digitalnog modela i stvarnih mera kostiju. Ispitivanje je sprovedeno na 10 kunića (5 ženki i 5 mužjaka), koji nisu imali nikakve deformitete kostiju. Trodimenzionalni modeli su dobijeni od podataka dvodimenzionalne mikro-kompjuterizovane tomografije mandibule kunića. Biometrijski podaci su dobijeni upotrebom istih mernih tačaka, kako od trodimenzionalnih modela tako i od stvarnih uzoraka kostiju. Uočen je značajan uticaj pola na najveću dužinu mandibule, dužinu od aboralne granice alveola trećeg molarnog zuba do infradentale, dužine dijasteme, visine vertikalnog ramusa (mereno u projekciji), udaljenost od incizora do oralne granice mentalnog foramena, udaljenost od aboralne granice mentalnog foramena do kaudalne granice mandibule i udaljenost retroalveolarnog foramena i kaudalne granice mandibule. Za ove mere, izračunate vrednosti za ženke su značajno veće u odnosu na mužjake ($p < 0,05$). Uočena je statistički značajna razlika između metoda samo u odnosu na dužinu bukalnog reda zuba i vrednosti visine vertikalnog ramusa ($p < 0,05$). Na osnovu rezultata ove studije, smatramo da 3D morfometrijsko merenje koštanog tkiva može tačno i pouzdano da se koristi kao alternativa uobičajenih merenja vršenih sa digitalnim kaliperom, naročito u oblasti anatomije i ortodontije.