

### ATRIAL FIBRILLATION – ECHOCARDIOGRAPHIC FINDINGS

KOVAČ M\*, TOTH J\*, HOLLERIDAR S\* and TAMBUR Z\*\*

*\*Horse veterinary clinic, Heiligenhaus - Germany \*\* Military Medical Academy, Belgrade*

(Received 17. November 2002)

*Seven horses with atrial fibrillation (of duration as long as 4 months) and ten normal warmblood horses were examined, using M-mode, 2-dimensional real-time (B-mode), pulsed-wave and colour coded Doppler echocardiography.*

*Horses with atrial fibrillation had significant increases in the mean values for left ventricular internal diameter, as well as left and right atrial chamber size and significant decreases of fractional shortening compared with normal horses. In horses with atrial fibrillation the M-mode echocardiogram revealed the lack of an A-peak at the level of the ventricles, immediately below the septal leaflet of the mitral valve. In horses with atrial fibrillation pulsed-wave Doppler analysed tracings of tricuspid valve outflow showed the absence of the A-peak (A wave), which is associated with atrial contraction.*

*The presence of a large systolic regurgitant jet associated with tricuspid valve insufficiency was detected with colour coded Doppler echocardiography in the right atrium in two horses.*

*M-mode, 2-dimensional real-time and Doppler echocardiography should be used to characterise valvular abnormalities and signs of atrial dilatation accurately as a prognostic indicator for therapy with quinidine sulphate.*

*Key words: horses, atrial fibrillation, echocardiography*

### INTRODUCTION

Atrial fibrillation is the most common arrhythmia in horses and is associated with poor performance and exercise intolerance. Its incidence in selected populations ranges from 0.34-2.5 % (Deem and Fregin, 1982; Bertone, 1984). There was no breed or sex predisposition for atrial fibrillation when compared to the general hospital population. The pathogenesis of atrial fibrillation is the subject of much debate. Myocarditis, endocarditis, valvular insufficiency with regurgitation, focal and diffuse myocardial fibrosis, vagotonia as well as a large atrial mass predispose the horse to development of re-entrant rhythms and atrial fibrillation (Eise and Holmes, 1971; Deem and Fregin, 1982; Moore and Spear, 1987, Bertone and Wingfield, 1987).

Most horses with atrial fibrillation have a history of poor performance (Deem and Fregin, 1982; Morris and Fregin, 1982). Otherwise atrial fibrillation is a stable

arrhythmia and horses with no other cardiovascular abnormalities can continue to work so long as they are not expected to make an intense effort. Namely, the cardiac output (CO) at rest is normal in most horses with atrial fibrillation but maximal CO during exercise (at higher heart rates) is limited because the atria make no contribution to filling the ventricular chambers (Muir *et al.*, 1984).

Electrocardiography (ECG) provides a reliable diagnosis of disease (Bertone, 1984; Moore and Spear, 1987; Kovač *et al.*, 2000), but does not provide complementary information on cardiac disease and haemodynamic status. In recent years echocardiography has become an important non-invasive diagnostic technique in which reflections of ultrasound waves are used to image cardiac structures. Earlier studies of applications to equine cardiology involved the use of unidimensional (M-Mode) examinations (Pipers and Hamlin 1977, Wingfield *et al.*, 1980). Recently, there have been reports on the diagnostic value of Doppler echocardiography (pulsed wave and colour coded Doppler echocardiography) (Reef *et al.*, 1989; Long, 1990; Marr and Reef, 1995; Blissitt and Bonaguara, 1995). This can be used to investigate the flow of blood within the cardiovascular system, to diagnose accurately valvular regurgitation, complex congenital defects as well as valvular stenosis and insufficiency.

The aims of this work were to describe and compare the clinical and echocardiographic (M-mode, 2-dimensional, pulse-wave and colour coded Doppler) findings in seven horses with atrial fibrillation and ten normal horses without cardiac disease.

#### MATERIALS AND METHODS

Observations were made on seven warmblood horses aged between 6 and 18 years (mean 12.6 +/- 3.1 years) with clinical evidence of atrial fibrillation of duration as long as 4 months. Additionally, ten normal warmblood horses aged between 6 and 16 years (mean 9.5 +/- 4.6) were observed. This control group of horses, had no history or evidence of cardiac dysfunction on clinical and electrocardiographic examination.

The electrocardiographic (ECG) examination was performed in all horses with the standard bipolar limb (Einthoven and unipolar limb) Goldberger methods. Data were recorded using an ECG – channel direct-writing recorder of the "Hellige EK-51" type. Recordings were made at a paper speed of 25 mm/s and a deflection (sensitivity) of 1 cm = 1 mV.

The echocardiographic examination (M-mode, 2-dimensional real-time, colour coded and pulsed-wave Doppler echocardiography) were recorded with horses in a standing position using a Vingmed CFM 725 ultrasound machine with a 2.5 MHz mechanical sector transducer. The maximum imaging depth of the equipment was 30 cm with a maximum sector angle of 90°. Images were recorded from the right and left sides of the thorax in different tomographic planes. The hair coat was clipped and acoustic coupling was achieved using ultrasound gel. The horse was positioned with the appropriate foreleg slightly abducted so that the olecranon process was free from the thoracic wall.

The recommendations of the American Society of Echocardiography were followed for all M-mode measurements (Sahn *et al.*, 1978) in the right parasternal short axis view. Systolic measurements were taken during the maximum excursion of the ventricular septum. The following M-mode measurements were made at the chordal level: Left ventricular internal diameter in systole (LVIDs) and diastole (LVIDd); interventricular septal thickness in systole (IVSs) and diastole (IVSd). The left ventricular measurement was used to calculate the fractional shortening (FS %) using the following equation:

$$FS\% = \frac{LVIDd - LVIDs}{LVIDd} \times 100$$

During 2 DE examinations the transducer positions and orientations used were suggested by Stadler *et al.* (1988). Measurement in 2D- echocardiography was in the right caudal long axis (RCLA). The right and left atrial chamber diameter was measured in this mode at the valvular level.

All the 2 DE images and Doppler echocardiographic results were observed on a monitor screen and recorded on a video recorder.

Differences between mean values were compared using Student's t-test.

## RESULTS

### *Clinical and electrocardiographic findings in horses with atrial fibrillation*

Exercise intolerance (n=6) and respiratory signs (cough, respiratory murmurs) (n=3) were the most common presenting signs in horses with atrial fibrillation. The heart rate ranged from 30-72 beats per minute (mean 42 +/- 6.6 beats/min). Auscultation of the heart revealed an irregular heart rhythm and absent fourth heart sound in all these horses. Additionally, three of the seven horses had holosystolic murmurs. One horse had prominent systolic jugular pulsations.

All horses revealed an absence of P waves on the ECG. Instead, fibrillation or „f” waves were seen in the baseline (Figure 1). The number of atrial impulses/minute was between 400 - 450. The QRS-T complexes were normal in morphology and duration, but the ventricular rate response was quite irregular.

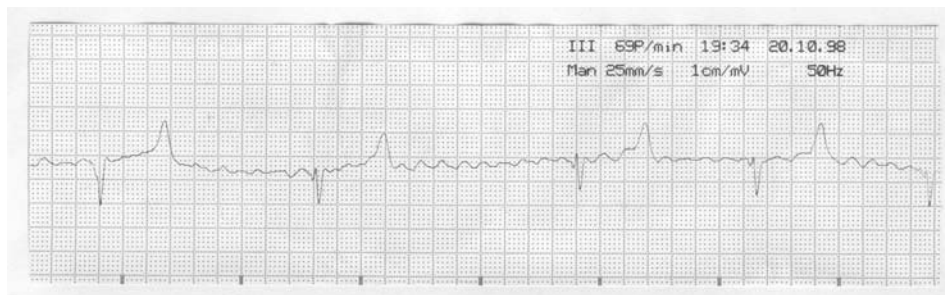

Figure 1. Limb ECG, showing the atrial fibrillation (absence of P-waves) in a horse

*Echocardiographic findings and measurements in M-mode*

In horses with atrial fibrillation the M-mode echocardiogram at the level of the ventricles, immediately below the septal leaflet of the mitral valve revealed the lack of an A-peak and an irregular rhythm with diastolic undulation (Figure 2). The „M" configuration of the flow and the echocardiographic anterior mitral valve motion were lost (because of the absence of atrial filling), in comparison with the normal horses.

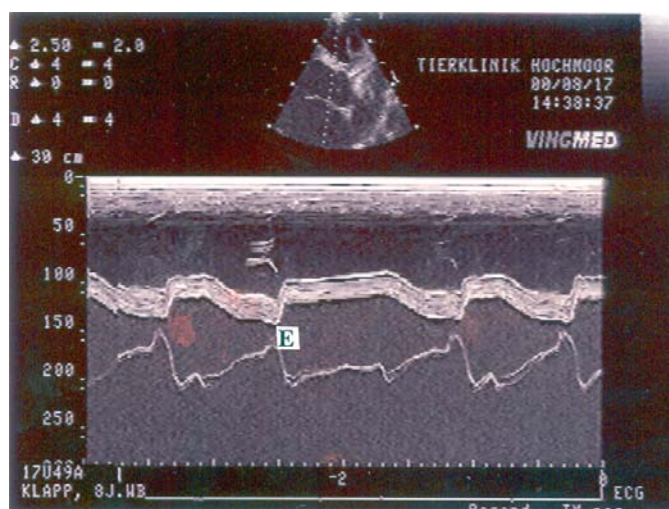


Figure 2. M-mode echocardiogram obtained at the level of the ventricles, showing the mitral valve with the lack of an A-peak, a irregular rhythm with diastolic undulation.

The mean values with standard deviation of the internal diameters of the left ventricle in the right parasternal short-axis view are given in Table 1. There were significant differences ( $p < 0.001$ ) in the left ventricular internal diameter in systole, as well as in diastole between the horses with atrial fibrillation and the control group.

Table 1. Cardiac measurements in cm using M-mode echocardiography

Parameter	Normal horses		Horses with atrial fibrillation		Significant
	Mean	SD	Mean	SD	
LVIDs	7.24	0.86	9.57	1.44	0.001
LVIDd	10.38	0.89	12.34	1.05	0.001
IVSs	4.02	0.63	4.34	0.52	n.s.
IVSd	3.12	0.44	3.09	0.36	n.s.
FS%	30.25	8.46	22.44	7.23	0.001

There was a significant difference ( $p < 0.001$ ) also in the fractional shortening between horses with atrial fibrillation (Figure 3) and normal horses.

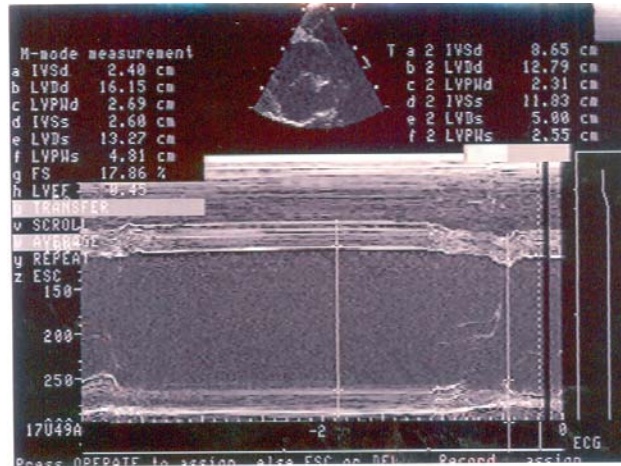


Figure 3. Echocardiogram a horse with atrial fibrillation obtained at the level of the ventricles showing decreases of fractional shortening (FS = 17.84%) of the left ventricle.

#### 2 D - echocardiographic findings

In horses with atrial fibrillation the mean internal diastole diameter of the left atrial chamber was 14.34 cm ( $\pm 2.4$ ) (Figure 4). This was significantly ( $p < 0.001$ ) increased in comparison with the control group of horses (mean 11.23  $\pm$  1.89).

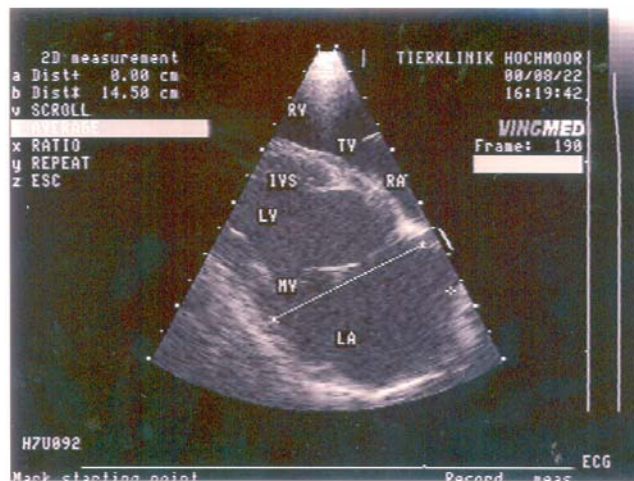


Figure 4. Echocardiogram in a horse with atrial fibrillation obtained in the right caudal long axis showing dilatation of the left atrium ( $r = 14.5$  cm).



In horses with atrial fibrillation the mean internal diastole diameter of the right atrial chamber was 10.23 cm (+/- 1.64). In control horses the right atrial diameter in diastole was 8.23 cm (+/- 1.02), which was significantly less ( $p < 0.001$ ) than in the horses with atrial fibrillation.

#### *Doppler echocardiography*

In horses with atrial fibrillation pulsed wave Doppler tracings of tricuspid valve outflow showed absence of the A-peak (A wave), which is associated with lack of atrial contraction. In normal horses the tricuspid inflow pattern always showed the rapid filling phase of the ventricle (E wave) and the atrial contraction (A wave).

Colour-coded Doppler gave the direction of blood flow and velocity superimposed on a two-dimensional image. In normal horses without cardiac diseases it is the convention that blood flowing away from the transducer is coded in red and blood flowing to the transducer is coded in blue. In horses with valvular regurgitation, disturbed flow is shown in green. Large regurgitant jets with turbulent blood flow and abnormal direction of blood flow (associated with tricuspid valve insufficiency) were detected in 2 horses (Figure 5), while small regurgitant jets of the mitral valve were observed in 1 horse.

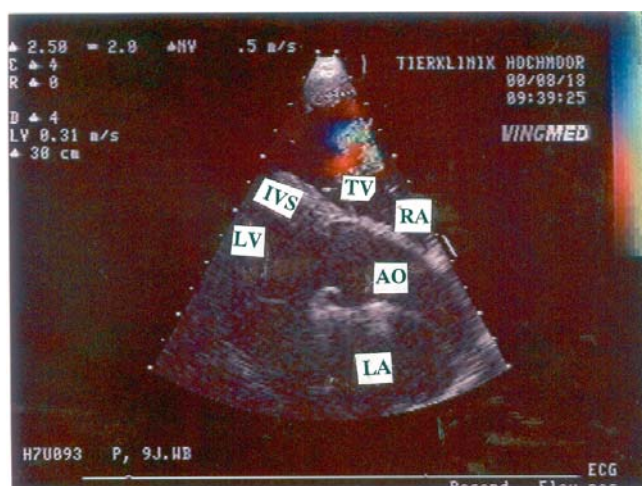


Figure 5. Colour-flow Doppler echocardiography recording from a horse with atrial fibrillation and tricuspid valve insufficiency (coded green – regurgitant jet)

#### DISCUSSION

Doppler echocardiography is a noninvasive method of evaluating the velocity, direction and turbulence of intracardiac blood flow. The *in vivo* 2 D and M-mode echocardiography measurements corresponded well with anatomical sections (Vörös *et al.*, 1990). These results suggest that echocardiography is a reli-

able method for accurate anatomical evaluation of the equine heart and indicate a potential application of quantitative two dimensional echocardiography in the living horse.

Our results for the ventricular and atrial internal diameters in systole and diastole in normal horses greater than those obtained in the unguided M-mode studies of O'Callaghan (1985) and Pipers and Hamlin (1977). This may be attributed to the larger bodyweights of the horses in our study (in mean 500 kg). The average weight of the horses in the study of Pipers and Hamlin (1977) was 300 kg.

In the horses with atrial fibrillation of at least 4 months duration both atria were dilated, as well as the left ventricle. The right ventricle internal diameter was not measured in our study, but it was probably dilated too.

Stadler *et al.* (1994) found that horses with atrial fibrillation had atrial dilatation in 82 % cases. This dilatation of the atria depended on disease duration. The myocardium dilatation with particular biatrial dilatation can be explained by volume overload, impaired coronary perfusion and valvular insufficiency as well as global reduction of LV systolic function because of decreased ventricular filling.

The shortening fraction percentage (FS %) expresses an index of cardiac contractility (Pipers and Hamlin, 1977; Bonagura, 1985). The values for left ventricular shortening fraction in horses with atrial fibrillation in our study were decreased compared with those in normal horses. This decrease in fractional shortening is probably multifactorial in origin but is related in part to decreased preload from loss of the atrial contribution to ventricular filling. Stadler *et al.* (1994) and Reef *et al.* (1995) found that such horses also had a slightly reduced LV shortening fraction, which returned to normal once the horse had been converted to sinus rhythm.

Conversion of atrial fibrillation to sinus rhythm using quinidine sulfate has been successful in many horses, using a variety of treatment plans (Rose and Davis, 1977; Morris and Fregin, 1982; Muir and McGuirk, 1984; Reef *et al.*, 1995).

An excellent prognosis for conversion (>95 % conversion rate) may be given for horses with a heart rate of less than or equal to 60 beats/min and/or less than 4 months duration (Reef *et al.*, 1988), i.e. the younger the horse when the arrhythmia occurs and the shorter the time for which it has been present, the better the prognosis is for permanent cardioversion. Horses with other cardiac diseases (AV insufficiency) may be more difficult to convert to sinus rhythm and have a higher recurrence rate too (Morris and Fregin, 1982).

The echocardiographic evaluation of atrial diameters with 2-dimensional real-time and detection of valvular regurgitation with Doppler echocardiography seems to be a reliable method to predict therapeutic success with quinidine sulfate in horses with atrial fibrillation, as well as in the diagnosis of other cardiac diseases. Moreover, potential applications of echocardiography also exist in equine intensive care units, for monitoring cardiac function during anesthesia and in areas such as equine exercise physiology.

Address for correspondence:  
Kovač M  
Horse veterinary clinic,  
Flurweg 20, 42579, Heiligenhaus - Germany

## REFERENCES

1. Bertone JJ, 1984, Atrial fibrillation in horses, Diagnosis, prognosis, treatment. *Equine Pract.*, 6, 6.
2. Bertone JJ, Wingfield WE, 1987, Atrial fibrillation in horses, *Comprnd Contin Educ. Prac. Vet*, 9, 763.
3. Blissitt KJ, Bonagura JD, 1955, Colour flow Doppler echocardiography in normal horses, *Equine Vet J.*, 19, 47-55.
4. Deem DA, Fregin GF, 1982, Atrial fibrillation in horses, *JAVMA*, 180, 261.
5. Else RW, Holmes JR, 1971, Pathological changes in atrial fibrillation in the horse. *Equine Vet. J.*, 3, 56-64.
6. Holmes JR, Henigan M, Williams RB, 1986, Paroxysmal atrial fibrillation in racehorse, *Equine Vet. J.*, 18, 37.
7. Kovac M, Scheidemann W, Toth J, 2000, Electrocardiographic changes during hyperinfusion therapy by COPD-Horses. *Proceedings of XVI Germany Congress of Equine Medicine, Wiesbaden, März, Germany*, 255-7.
8. Long KJ, 1990, Doppler echocardiography in the horse, *Equine Vet. Education.*, 2, 1, 15-7.
9. Marr CM, Reef VB, 1995, Physiological valvular regurgitation in clinically normal young racehorses: prevalence and two-dimensional colour flow Doppler echocardiographic characteristics. *Equine Vet J.*, 19, 56-62.
10. Moore EN, Spear JF, 1987, Electrophysiological studies on atrial fibrillation, *Heart Vessels Suppl.*, 2, 32.
11. Morris DD, Fregin GF, 1982, Atrial fibrillation in horses: Factors associated with response to quinidine sulfate in 77 clinical cases, *Cornell Vet J*, 72, 339-49.
12. Muir WW, Mc Guirk SM, 1984, Hemodynamics before and after conversion of atrial fibrillation to normal sinus rhythm in horses, *JAVMA*, 184, 965.
13. OCallaghan MW, 1985, Comparison of echocardiographic and autopsy measurements of cardiac dimension in the horse, *Equine Vet J.*, 17, 361-8.
14. Pipers FS, Hamlin RL, 1977, Echocardiography in the horse, *J Am Vet Med. Ass*, 170, 815-9.
15. Reef VB, Lalezary K, De Boo J, Spencer PA, Dik KJ, 1989, Pulsed-wave Doppler evaluation of intracardiac blood flow in 30 clinically normal Standardbred horses, *Am J Vet Res*, 50, 75-84.
16. Reef VB, Levitan CW, Spencer PA, 1988, Factors affecting prognosis and conversion in equine atrial fibrillation, *J. Vet. Intern Med.*, 2, 1.
17. Reef VB, Reimer JM, Spencer PA, 1995, Treatment of atrial fibrillation in horses – new perspectives. *J. Vet. Intern Med*, 9, 57.
18. Rose RJ, Davis PE, 1977, Treatment of atrial fibrillation in three racehorses. *Equine Vet J.*, 9, 68.
19. Sahn DJ, de Maria A, Kisslo J, Weymann A, 1978, Recommendations regarding quantitation in M-mode echocardiography : Result of a survey of echocardiographic measurements, *Circulation*, 58, 1072-83.
20. Stadler PU, D'Agostino PU, Deegen E, 1988, Methodik der Schnittbildechokardiographie beim Pferd. *Pferdeheilkunde*, 4, 161-74.
21. Stadler P, Deegen E, Kroker K, 1994, Echocardiography and therapy of atrial fibrillation in horses. *DTW Dtsch Tierarztl Wochenschr*, 101, 190.
22. Vorös K, Holmes JR, Gibbs C, 1990, Anatomical validation of two-dimensional echocardiography in the horse. *Equine Vet J.*, 22, 6, 392-7.
23. Wingfield WE, Miller C, Voss JL, Benett DG, Breukels J, 1980, Echocardiography in assessing mitral valve motion in 3 horses with fibrillation, *Equine Vet J.*, 12, 181-4.



## ATRIJALNA FIBRILACIJA – EHOKARDIOGRAFSKI NALAZI

KOVAČ M, TOTH J, HOLLERIDAR S i TAMBUR Z

### SADRŽAJ

Ultrazvučno ispitivanje srca u M-modusu, 2-dimenzionalnom B- modusu, kao i „dopler“ pulzaciono talasnom i obojeno-kodiranom ehokardiografijom izvršeno je u 7 konja sa fibrilacijom pretkomora (koja traje duže od 4 meseca), kao i kod deset polukrvnih zdravih konja.

Konji sa fibrilacijom pretkomora imali su značajno povećavanje unutrašnjeg dijametra leve komore, signifikantnu dilataciju pretkomora, kao i značajno smanjivanje frakcionalnog skraćivanja leve komore u poređenju sa zdravim konjima. U konja sa fibrilacijom pretkomora u M-modusu nađene su promene pokretanja mitralnih zalistaka, u smislu izostajanja A- talasa. U konja sa fibrilacijom pretkomora takođe su uočene promene u pulsacionom-talasnom „dopler“ ultrazvučnom ispitivanju u smislu izostajanja A - talasa, što je u vezi sa odsustvom normalnih pretkomornih kontrakcija.

Sa obojeno-kodiranom dopler ehokardiografijom uočene su promene u dva konja sa fibrilacijom pretkomora u smislu snažnog sistoličnog regurgacionog vraćanja krvi na nivou desne pretkomore, što je ukazvalo na trikuspidalnu insuficijenciju.

Ultrazvučno ispitivanje srca u M-modusu, 2-dimenzionalnom B- modusu i „dopleru“ potrebno je provesti pažljivo radi ispitivanja eventulanih promena na srčanim zaliscima, kao i pojavu dilatacije pretkomora, sve u smislu prognoze terapije – (kardioverzije) sa chinidin sulfatom.